

BÖLÜM 20

Yenidoğanın Gastrointestinal Acilleri



Başak KAYA GÜRSOY¹

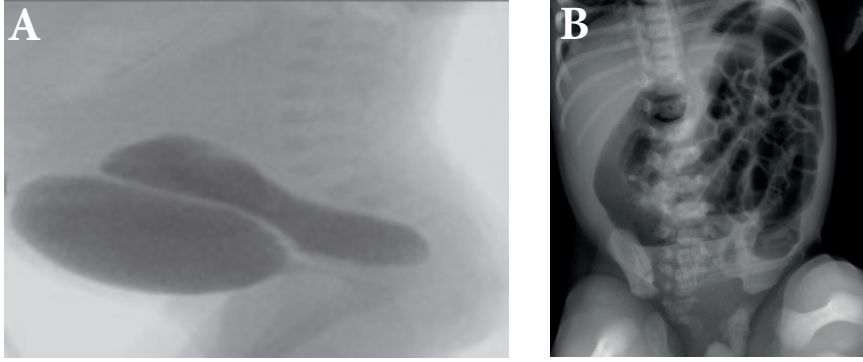
Yenidoğan gastrointestinal acilleri, özofagustan kolona kadar sindirim sistemi boyunca herhangi bir yerde meydana gelebilecek çeşitli anormalliklerin biraraya gelmesinden kaynaklanır. Teknolojideki gelişmeler ile doğum öncesi görüntüleme yöntemleri ile bu hastalıkların öngörülebilme sıklığı artmakla birlikte, bu yenidoğanlar sıklıkla acil olarak başvururlar. Dikkatli bir anamnez, tam bir fizik muayene ve doğru tanı için korele görüntüleme yöntemlerinin kombinasyonunu gerektiren kapsamlı bir değerlendirme acilen yapılmalıdır. Bu popülasyonda, potansiyel mortalite ve morbiditeyi en aza indirmek için doğru ve zamanında teşhis esastır.

Gastrointestinal sistem acilleri, üst ve alt gastrointestinal sistem acilleri olarak ele alınmaktadır. Gastrointestinal sistem acillerinden şüphelenildiğinde (öykü, fizik muayene, klinik durum değerlendirilerek) üst ve alt gastrointestinal sistem acillerinin ayrımı için, farklı görüntüleme yöntemleri kullanılmaktadır.

Görüntüleme Yöntemleri

Radyografi, genellikle şüpheli bir gastrointestinal acil durum olan yenidoğanların görüntüleme değerlendirmesinde ilk adımdır. Sol lateral dekübitus veya cross table lateral görünümü gibi ikinci bir görünümün eklenmesi genellikle ektopik hava, hava-sıvı seviyeleri ve rektal gazın değerlendirilmesinde yardımcı olabilir.

¹ Uzm. Dr. Dr. Sami Ulus Kadın Doğum Çocuk Sağlığı Hastalıkları Eğitim ve Araştırma Hastanesi
Neonatoloji, bskgrsy@gmail.com



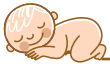Şekil 14. Anorektal malformasyon, 14A. Rektovezikal fistül, Sistüetrogramda mesaneye verilen kontrastın rektosigmoid kolona geçişi 14B. Anal atrezi, direkt grafide pelvik bölgede gaz geçişi yok (Dr. Başak Kaya Gürsoy'un bireysel arşivinden)

Tedavi

ARM'li bir yenidoğana teşhis konulduktan sonra, ilk yönetim hidrasyon ve sepsisten kaçınmaya odaklanmak olmalıdır. Acil olarak cerrahi müdahaleye gerek yoktur. Öncesinde yenidoğan yaşamının ilk 24- 36 saatinde kapsamlı bir tanısal değerlendirmeden geçmelidir (111). Sıvı ve antibiyotik tedavisi başlanarak, kusma ve aspirasyon olasılığını önlemek ve mide dekompresyonu için nazogastrik tüp yerleştirilmelidir. Alçakta yatan basit bir ARM tedavisinde primer anoplasti, yüksek veya karmaşık bir malformasyonda kolostomiye takiben, 4-8 hafta sonra kesin cerrahi onarım gerekmektedir.

KAYNAKLAR

1. Hernanz-Schulman M, Sells LL, Ambrosino MM, et al. Hypertrophic pyloric stenosis in the infant without a palpable olive: accuracy of sonographic diagnosis. *Radiology*. 1994;193:771-776.
2. Stunden RJ, LeQuesne GW, Little KE . The improved ultrasound diagnosis of hypertrophic pyloric stenosis. *Pediatr Radiol*. 1986;16:200-205.
3. Hiorns MP. Gastrointestinal tract imaging in children: current techniques. *Pediatr Radiol*. 2011; 41:42-54.
4. Epelman M, Daneman A, Navarro OM, et al. Necrotizing enterocolitis: review of state-of-the-art imaging findings with pathologic correlation. *Radiographics : a review publication of the Radiological Society of North America, Inc.* 2007;27:285-305.
5. Anupindi SA, Halverson M, Khwaja A, et al. Common and uncommon applications of bowel ultrasound with pathologic correlation in children. *AJR American journal of roentgenology*. 2014;202:946-959.



6. Cassina M, Ruol M, Pertile R, et al. Prevalence, characteristics, and survival of children with esophageal atresia: A 32-year population-based study including 1,417,724 consecutive newborns. *Birth Defects Research Part A: Clinical and Molecular Teratology*. 2016;106:542-548.
7. Clark DC. Esophageal atresia and tracheoesophageal fistula. *American family physician*. 1999;59:910.
8. Jolley SG, Johnson DG, Herbst JJ, et al. An assessment of gastroesophageal reflux in children by extended pH monitoring of the distal esophagus. *Surgery*. 1978;84:16-24.
9. Scott DA. Esophageal atresia/tracheoesophageal fistula overview. 2018.
10. Petrosyan M, Estrada J, Hunter C, et al. Esophageal atresia/tracheoesophageal fistula in very low-birth-weight neonates: improved outcomes with staged repair. *Journal of pediatric surgery*. 2009;44:2278-2281.
11. Galea R, Said E. Infantile hypertrophic pyloric stenosis: an epidemiological review. *Neonatal Network*. 2018;37:197-204.
12. Abdellatif M, Ghozy S, Kamel MG, et al. Association between exposure to macrolides and the development of infantile hypertrophic pyloric stenosis: a systematic review and meta-analysis. *European journal of pediatrics*. 2019;178:301-314.
13. Rosenthal YS, Chodick G, Grossman Z, et al. The incidence of infantile hypertrophic pyloric stenosis and its association with folic acid supplementation during pregnancy: A nested case-control study. *Journal of pediatric surgery*. 2019;54:701-706.
14. Galea R, Said E. Infantile Hypertrophic Pyloric Stenosis: An Epidemiological Review. *Neonatal network*. 2019;37:197-204.
15. Kaye P. Acquired pyloric stenosis resulting in hypokalaemic, hyperchloraemic normal anion gap metabolic acidosis. Persistent vomiting in an adult: cause and effect. *Case Reports* 2018:bcr-2017-222800.
16. Goldman-Yassen AE, Gross J, Novak I, et al. Identification of clinical parameters to increase the diagnostic yield of the non-emergent upper gastrointestinal series in pediatric outpatients. *Pediatric radiology*. 2019;49:162-167.
17. Bašković M, Župančić B, Lesjak N, Et Al. Hypertrophic Pyloric Stenosis-Five-Year Retrospective Analysis. *Acta medica Croatica*. 2016;70:103-106.
18. Müller M, Morger R, Engert J . Pyloric atresia: report of four cases and review of the literature. *Pediatric surgery international*. 1990;5:276-279.
19. Samad L, Siddiqui EF, Arain MA, et al. Pyloric atresia associated with epidermolysis bullosa—three cases presenting in three months. *Journal of pediatric surgery*. 2004; 39:1267-1269.
20. Ilce Z, Erdogan E, Kara C, ark. Pyloric atresia: 15-year review from a single institution. *Journal of pediatric surgery*. 2003;38:1581-1584.
21. Moore CC. Congenital gastric outlet obstruction. *Journal of pediatric surgery*. 1989;24:1241-1246.
22. Maman E, Maor E, Kachko L, et al. Epidermolysis bullosa, pyloric atresia, aplasia cutis congenita: histopathological delineation of an autosomal recessive disease. *American journal of medical genetics*. 1998;78:127-133.
23. Dank JP, Kim S, Parisi MA, et al. Outcome After Surgical Repair of Junctional Epidermolysis Bullosa-Pyloric Atresia Syndrome: A Report of 3 Cases and Review of the Literature. *Archives of dermatology*. 1999;135:1243-1247.
24. Chang C-H, Perrin EV, Bove KE. Pyloric atresia associated with epidermolysis bullosa: special reference to pathogenesis. *Pediatric pathology*. 1983;1:449-457



25. Shaw DW, Fine J-D, Piacquadio DJ, et al. Gastric outlet obstruction and epidermolysis bullosa. *Journal of the American Academy of Dermatology*. 1997;36:304-310
26. Morris JK, Springett AL, Greenlees R, et al. Dias C Trends in congenital anomalies in Europe from 1980 to 2012. *PloS one*. 2018;13:e0194986.
27. Blumer SL, Zucconi WB, Cohen HL, et al. The vomiting neonate: a review of the ACR appropriateness criteria and ultrasound's role in the workup of such patients. *Ultrasound quarterly*. 2004;20:79-89.
28. Escobar MA, Ladd AP, Grosfeld JL, et al. Duodenal atresia and stenosis: long-term follow-up over 30 years. *Journal of pediatric surgery*. 2004;39:867-871.
29. Graziano K, Islam S, Dasgupta R, et al. Asymptomatic malrotation: diagnosis and surgical management: an American Pediatric Surgical Association outcomes and evidence based practice committee systematic review. *Journal of pediatric surgery*. 2015;50:1783-1790.
30. Aboagye J, Goldstein SD, Salazar JH, et al. Age at presentation of common pediatric surgical conditions: reexamining dogma. *Journal of pediatric surgery*. 2014;49:995-999.
31. Marseglia L, Manti S, D'Angelo G, et al. Gastroesophageal reflux and congenital gastrointestinal malformations. *World Journal of Gastroenterology*. 2015; 21:8508
32. Nehra D, Goldstein AM. Intestinal malrotation: varied clinical presentation from infancy through adulthood. *Surgery*. 2011;149:386-393.
33. Loening-Baucke V, Kimura K. Failure to pass meconium: diagnosing neonatal intestinal obstruction. *American family physician*. 1999;60:2043.
34. Begin R, Racine T, Roy J-C. Value of capillary blood gas analyses in the management of acute respiratory distress. *American Review of Respiratory Disease*. 1975;112:879-881.
35. Messineo A, MacMillan JH, Palder SB, Filler RM (1992) Clinical factors affecting mortality in children with malrotation of the intestine. *Journal of pediatric surgery*. 1992;27:1343-1345.
36. Svetanoff WJ, Sobrino JA, Sujka JA, et al. Laparoscopic Ladd Procedure for the Management of Malrotation and Volvulus. *Journal of Laparoendoscopic & Advanced Surgical Techniques*. 2020;30:210-215.
37. Mangray H, Ghimenton F, Aldous C. Jejunio-ileal atresia: its characteristics and peculiarities concerning apple peel atresia, focused on its treatment and outcomes as experienced in one of the leading South African academic centres. *Pediatric surgery international*. 2020;36:201-207.
38. Adams SD, Stanton MP. Malrotation and intestinal atresias. *Early human development*. 2014;90:921-925.
39. Calisti A, Olivieri C, Coletta R, et al. Jejunioileal Atresia: Factors Affecting the Outcome and Long-term Sequelae. *Journal of clinical neonatology*. 2012;1:38-41.
40. Louw JH. Congenital intestinal atresia and stenosis in the newborn. Observations on its pathogenesis and treatment. *Annals of the Royal College of Surgeons of England*. 1959;25:209-234.
41. Puri P, Fujimoto T. New observations on the pathogenesis of multiple intestinal atresias. *J Pediatr Surg*. 1988;23:221-225.
42. Grosfeld JL, Ballantine TV, Shoemaker R. Operative management of intestinal atresia and stenosis based on pathologic findings. *J Pediatr Surg*. 1979;14:368-375.
43. Adams SD, Stanton MP. Malrotation and intestinal atresias. *Early Hum Dev*. 2014;90:921-925.



44. Zhu H, Gao R, Alganabi M, et al. Long-term surgical outcomes of apple-peel atresia. *J Pediatr Surg.* 2019;54:2503-2508.
45. Stollman TH, de Blaauw I, Wijnen MH, et al. Decreased mortality but increased morbidity in neonates with jejunoileal atresia; a study of 114 cases over a 34-year period. *J Pediatr Surg.* 2009;44:217-221.
46. Louw JH. Resection and end-to-end anastomosis in the management of atresia and stenosis of the small bowel. *Surgery.* 1967;62:940-950.
47. Kumaran N, Shankar KR, Lloyd DA, et al. Trends in the management and outcome of jejuno-ileal atresia. *European journal of pediatric surgery.* 2002;12:163-167.
48. Ghose I, Mason GC, Martinez D, et al. Hyperechogenic fetal bowel: a prospective analysis of sixty consecutive cases. *BJOG : an international journal of obstetrics and gynaecology.* 2000;107:426-429.
49. Phelps S, Fisher R, Partington A, et al. Prenatal ultrasound diagnosis of gastrointestinal malformations. *J Pediatr Surg.* 1997;32:438-440.
50. Dalla Vecchia LK, Grosfeld JL, West KW, et al. Intestinal atresia and stenosis: a 25-year experience with 277 cases. *Archives of surgery.* 1998;133:490-496.
51. Louw JH. Congenital intestinal atresia and severe stenosis in the newborn; a report on 79 consecutive cases. *South African journal of clinical science Suid-Afrikaanse tydskrif vir kliniese wetenskap.* 1952;3:109-129.
52. Sathe M, Houwen R. Meconium ileus in Cystic Fibrosis. *Journal of cystic fibrosis: official journal of the European Cystic Fibrosis Society* 16 Suppl. 2017;2:32-39.
53. Paradiso VF, Briganti V, Oriolo L, et al. Meconium obstruction in absence of cystic fibrosis in low birth weight infants: an emerging challenge from increasing survival. *Italian journal of pediatrics.* 2011;37:55.
54. Emil S, Nguyen T, Sills J, et al. Meconium obstruction in extremely low-birth-weight neonates: guidelines for diagnosis and management. *J Pediatr Surg.* 2004;39:731-737.
55. Shinohara T, Tsuda M, Koyama N. Management of meconium-related ileus in very low-birthweight infants. *Pediatrics international : official journal of the Japan Pediatric Society.* 2007;49:641-644.
56. Carlyle BE, Borowitz DS, Glick PL. A review of pathophysiology and management of fetuses and neonates with meconium ileus for the pediatric surgeon. *J Pediatr Surg.* 2012;47:772-781.
57. Berrocal T, Lamas M, Gutieérrez J, et al. Congenital anomalies of the small intestine, colon, and rectum. *Radiographics : a review publication of the Radiological Society of North America, Inc.* 1999;19:1219-1236.
58. Nam SH, Kim SC, Kim DY, et al. Experience with meconium peritonitis. *J Pediatr Surg.* 2007;42:1822-1825.
59. Eckoldt F, Heling KS, Woderich R, et al. Meconium peritonitis and pseudo-cyst formation: prenatal diagnosis and post-natal course. *Prenatal diagnosis.* 2003;23:904-908.
60. Shyu MK, Shih JC, Lee CN, et al. Correlation of prenatal ultrasound and postnatal outcome in meconium peritonitis. *Fetal diagnosis and therapy.* 2003;18:255-261.
61. Cuenca AG, Ali AS, Kays DW, et al. "Pulling the plug" management of meconium plug syndrome in neonates. *The Journal of Surgical Research.* 2012;175:43-46.
62. Buonpane C, Lautz TB, Hu YY. Should we look for Hirschsprung disease in all children with meconium plug syndrome? *J Pediatr Surg.* 2019;54:1164-1167.
63. Keckler SJ, St Peter SD, Spilde TL, et al. Current significance of meconium plug syndrome. *J Pediatr Surg.* 2008;43:896-898.



64. Stewart DR, Nixon GW, Johnson DG, et al. Neonatal small left colon syndrome. *Annals of surgery*. 1977;186:741-745.
65. Gordon PV. Understanding intestinal vulnerability to perforation in the extremely low birth weight infant. *Pediatric research*. 2009;65:138-144.
66. Khan RA, Mahajan JK, Rao KL. Spontaneous intestinal perforation in neonates: is surgery always indicated? *African journal of paediatric surgery*. 2011;8:249-251.
67. Pumberger W, Mayr M, Kohlhauser C, et al. Spontaneous localized intestinal perforation in very-low-birth-weight infants: a distinct clinical entity different from necrotizing enterocolitis. *Journal of the American College of Surgeons*. 2002;195:796-803.
68. Ward RM, Beachy JC. Neonatal complications following preterm birth. *BJOG : an international journal of obstetrics and gynaecology*. 2003;110 Suppl 20:8-16.
69. Yee WH, Soraisham AS, Shah VS, et al. Incidence and timing of presentation of necrotizing enterocolitis in preterm infants. *Pediatrics*. 2012;129:298-304.
70. Bell MJ, Ternberg JL, Feigin RD, et al. Neonatal necrotizing enterocolitis. Therapeutic decisions based upon clinical staging. *Annals of surgery*. 1978;187:1-7.
71. Hsueh W, Caplan MS, Qu XW, et al. Neonatal necrotizing enterocolitis: clinical considerations and pathogenetic concepts. *Pediatric and developmental pathology : the official journal of the Society for Pediatric Pathology and the Paediatric Pathology Society*. 2003;6:6-23.
72. Luig M, Lui K. Epidemiology of necrotizing enterocolitis--Part II: Risks and susceptibility of premature infants during the surfactant era: a regional study. *Journal of paediatrics and child health*. 2005;41:174-179.
73. Neu J, Mshvildadze M, Mai. A roadmap for understanding and preventing necrotizing enterocolitis. *Current gastroenterology reports*. 2008;10:450-457.
74. Buchheit JQ, Stewart DL. Clinical comparison of localized intestinal perforation and necrotizing enterocolitis in neonates. *Pediatrics*. 1994;93:32-36.
75. Kubota A, Yamanaka H, Okuyama H, et al. Focal intestinal perforation in extremely-low-birth-weight neonates: etiological consideration from histological findings. *Pediatr Surg Int*. 2007;23:997-1000.
76. Neu J. Preterm infant nutrition, gut bacteria, and necrotizing enterocolitis. *Current opinion in clinical nutrition and metabolic care*. 2015;18:285-288.
77. Niño DF, Sodhi CP, Hackam DJ. Necrotizing enterocolitis: new insights into pathogenesis and mechanisms. *Nature reviews Gastroenterology & hepatology*. 2016;13:590-600.
78. Lin PW, Stoll BJ. Necrotising enterocolitis. *Lancet (London, England)*. 2006;368:1271-1283.
79. Neu J, Walker WA. Necrotizing enterocolitis. *The New England journal of medicine*. 2011;364:255-264.
80. Gephart SM, McGrath JM, Effken JA, et al. Necrotizing enterocolitis risk: state of the science. *Advances in neonatal care : official journal of the National Association of Neonatal Nurses*. 2012;12:77-87.
81. Beeby PJ, Jeffery H. Risk factors for necrotising enterocolitis: the influence of gestational age. *Archives of disease in childhood*. 1992;67:432-435.
82. Guthrie SO, Gordon PV, Thomas V, et al. Necrotizing enterocolitis among neonates in the United States. *Journal of perinatology : official journal of the California Perinatal Association*. 2003;23:278-285.
83. Berseth CL. Gastrointestinal motility in the neonate. *Clinics in perinatology*. 1996;23:179-190.



84. Berseth CL. Gestational evolution of small intestine motility in preterm and term infants. *J Pediatr.* 1989;115:646-651.
85. Martin CR, Walker WA. Intestinal immune defences and the inflammatory response in necrotising enterocolitis. *Seminars in fetal & neonatal medicine.* 2006;11:369-377.
86. Yu L, Tian J, Zhao X, et al. Bowel Perforation in Premature Infants with Necrotizing Enterocolitis: Risk Factors and Outcomes. *Gastroenterology research and practice.* 2016;6:134-187.
87. Munaco AJ, Veenstra MA, Brownie E, et al. Timing of optimal surgical intervention for neonates with necrotizing enterocolitis. *The American surgeon.* 2015;81:438-443.
88. Nasuf AWA, Ojha S, Dorling J. Oropharyngeal colostrum in preventing mortality and morbidity in preterm infants. *The Cochrane database of systematic reviews.* 2018;9:119-121.
89. Cortez J, Makker K, Kraemer DE, et al. Maternal milk feedings reduce sepsis, necrotizing enterocolitis and improve outcomes of premature infants. *Journal of perinatology : official journal of the California Perinatal Association.* 2018;38:71-74.
90. Shulhan J, Dicken B, Hartling L, et al. Current Knowledge of Necrotizing Enterocolitis in Preterm Infants and the Impact of Different Types of Enteral Nutrition Products. *Advances in nutrition.* 2017;8:80-91.
91. Renfrew MJ, Craig D, Dyson L, et al. Breastfeeding promotion for infants in neonatal units: a systematic review and economic analysis. *Health technology assessment.* 2009;13:1-146.
92. Newburg DS. Neonatal protection by an innate immune system of human milk consisting of oligosaccharides and glycans. *Journal of animal science.* 2009;87:26-34.
93. Buescher ES. Anti-inflammatory characteristics of human milk: how, where, why. *Advances in experimental medicine and biology.* 2001;501:207-222.
94. Lin HC, Hsu CH, Chen HL, et al. Oral probiotics prevent necrotizing enterocolitis in very low birth weight preterm infants: a multicenter, randomized, controlled trial. *Pediatrics.* 2008;122:693-700.
95. Lin HC, Su BH, Chen AC, et al. Oral probiotics reduce the incidence and severity of necrotizing enterocolitis in very low birth weight infants. *Pediatrics.* 2005;115:1-4.
96. Lin HC, Su BH, Oh W. Oral probiotics prevent necrotizing enterocolitis. *J Pediatr.* 2006;148:849-850.
97. Neu J. Probiotics and necrotizing enterocolitis. *Clinics in perinatology* 2014;41:967-978.
98. Robinson J. Probiotics for prevention of necrotizing enterocolitis in preterm infants. *Evidence-based child health : a Cochrane review journal.* 2014;9:672-674.
99. Blickman J.G., Parker B.R., Barnes P.D. (2009). *Pediatric radiology: 3rd edition.* Production: Mosby
100. Putnam LR, John SD, Greenfield SA, et al. The utility of the contrast enema in neonates with suspected Hirschsprung disease. *J Pediatr Surg.* 2015;50:963-966.
101. Cowles RA, Berdon WE, Holt PD, et al. Neonatal intestinal obstruction simulating meconium ileus in infants with long-segment intestinal aganglionosis: radiographic findings that prompt the need for rectal biopsy. *Pediatr Radiol.* 2006;36:133-137.
102. Davenport M, Bianchi A, Doig CM, et al. Colonic atresia: current results of treatment. *Journal of the Royal College of Surgeons of Edinburgh.* 1990;35:25-28.
103. Etensel B, Temir G, Karkiner A, et al. Atresia of the colon. *J Pediatr Surg.* 2005;40:1258-1268.
104. Komuro H, Takahashi MI, Matoba K, et al. Rare association of severe hypoplasia of the abdominal aorta with imperforate anus, colonic atresia, and choledochal cyst. *Pediatr Surg Int.* 2006; 22:289-292.



105. Nijagal A, Ozgediz D, Feldstein VA, et al. Colonic atresia and choledochal cyst: a rare combination. *Pediatr Surg Int.* 2009;25:113-115.
106. Goodwin S, Schlatter M, Connors R. Imperforate anus and colon atresia in a newborn. *J Pediatr Surg.* 2006;41:583-585.
107. Maitra S, Sarkar R. Anorectal malformation associated with small and large bowel atresias: a rare association. *Journal of neonatal surgery.* 2012; 1:59.
108. Siminas S, Burn S, Corbett H. Colon atresia and frontal encephalocele: a rare association. *J Pediatr Surg.* 2011;46:25-28.
109. Szavay PO, Schliephake H, Hubert O, et al. Colon atresia, facial hemiplasia, and anophthalmia: a case report. *J Pediatr Surg.* 2002;37:1498-1500.
110. Cabrera Valerio C, Díaz Z, Alcántara E, et al. Colonic atresia: a rare entity in the newborn. A six-case report and a bibliographic review. *Cirugia pediátrica : organo oficial de la Sociedad Espanola de Cirugia Pediátrica.* 2021;34:74-78.
111. Levitt MA, Peña A. Anorectal malformations. *Orphanet journal of rare diseases.* 2007;2:33.
112. Watanabe Y, Ando H, Seo T, et al. Three-dimensional image reconstruction of an anorectal malformation with multidetector-row helical computed tomography technology. *Pediatr Surg Int.* 2003; 19:167-171.
113. Cho S, Moore SP, Fangman T. One hundred three consecutive patients with anorectal malformations and their associated anomalies. *Archives of pediatrics & adolescent medicine.* 2001;155:587-591.
114. Endo M, Hayashi A, Ishihara M, et al. Analysis of 1,992 patients with anorectal malformations over the past two decades in Japan. Steering Committee of Japanese Study Group of Anorectal Anomalies. *J Pediatr Surg.* 1999;34:435-441.
115. Kluth D. Embryology of anorectal malformations. *Seminars in pediatric surgery.* 2010;19:201-208.
116. Alamo L, Meyrat BJ, Meuwly JY, et al. Anorectal Malformations: Finding the Pathway out of the Labyrinth. *Radiographics : a review publication of the Radiological Society of North America, Inc.* 2013;33:491-512.
117. Niedzielski JK. Invertography versus ultrasonography and distal colostography for the determination of bowel-skin distance in children with anorectal malformations. *European journal of pediatric surgery : official journal of Austrian Association of Pediatric Surgery.* 2005;15:262-267.