



### ANTENATAL HİDRONEFROZ NEDENİYLE BAŞVURAN 12 GÜNLÜK KIZ OLGU

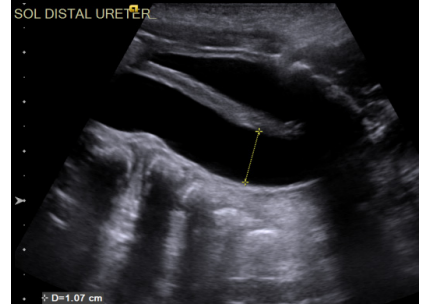
Ömer Barış YÜCEL<sup>1</sup>

On iki günlük kız bebek antenatal hidronefroz sebebi ile yönlendirildi. Antenatal 32. gestasyonel haftada yapılan ultrasonografide sağ böbreğin normal olarak değerlendirildiği, sol böbrekte grade 2 hidroüreteronefroz saptandığı, üreter çapının 10 mm olduğu öğrenildi (Resim 1).

#### Soru 1. Bu hasta için ön tanınız nedir?

Antenatal hidroüreteronefroz saptanan bu vakada tanı megaüreterdir. Ancak megaüreter tanımı, bir hastalığın sebebini ya da prognozunu açıklamamakta sadece retrovezikal üreter çapının 7 mm'den büyük olduğunu ifade etmektedir <sup>1</sup>.

Megaüreterler, altta yatan etiyolojiye göre primer ve sekonder olarak ikiye ayrılabilir. Üreterin kendine ait bir patolojisi nedeniyle oluşanlara primer, mesane veya üretra patolojilerine ikincil oluşanlara sekonder megaüreter denir. Ayrıca eşlik eden VUR ve obstrüksiyon durumuna göre 4 sınıfa ayrılabilir <sup>2</sup>.



Resim 1

<sup>1</sup> Uzm. Dr., Ege Üniversitesi Tıp Fakültesi, Çocuk Cerrahisi AD, Çocuk Ürolojisi BD, omer.baris.yucel@ege.edu.tr



Başarılı işlem sonrası MAG-3 ile böbreğin boşalmasında, glomerüler filtrasyonda düzelme ve takipte böbrek fonksiyonun korunduğu görülmüştür. Ayrıca böbrek fonksiyonundaki bozulma nedeniyle cerrahi geçiren POM hastalarında uzun dönem takipte yüksek tansiyon riskinin artmadığı gösterilmiştir<sup>53,67</sup>.

## Kaynaklar

1. Farrugia MK, Hitchcock R, Radford A, ve ark. British Association of Paediatric Urologists consensus statement on the management of the primary obstructive megaureter. *J Pediatr Urol.* Feb 2014;10(1):26-33. doi:10.1016/j.jpuro.2013.09.018
2. King LR. Megaloureter: definition, diagnosis and management. *J Urol.* Feb 1980;123(2):222-3. doi:10.1016/s0022-5347(17)55867-x
3. Koff SA. Problematic ureteropelvic junction obstruction. *J Urol.* Aug 1987;138(2):390. doi:10.1016/s0022-5347(17)43157-0
4. Docimo SG, Canning D, El-Khoury AE, ve ark. *The Kelalis--King--Belman Textbook of Clinical Pediatric Urology.* 2018.
5. Shokeir AA, Nijman RJ. Primary megaureter: current trends in diagnosis and treatment. *BJU Int.* Nov 2000;86(7):861-8. doi:10.1046/j.1464-410x.2000.00922.x
6. Peters C, Mandell J, Treves T, ve ark. The "well tempered" diuretic renogram: a standard method to examine the asymptomatic neonate with hydronephrosis or hydroureteronephrosis. A report from combined meetings of The Society for Fetal Urology and members of The Pediatric Nuclear Medicine Council--The Society of Nuclear Medicine. *Journal of nuclear medicine : official publication, Society of Nuclear Medicine.* 1992 1992;33(11):2047-2051.
7. Pirker ME, Rolle U, Shinkai T, ve ark. Prenatal and postnatal neuromuscular development of the ureterovesical junction. *J Urol.* Apr 2007;177(4):1546-51. doi:10.1016/j.juro.2006.11.081
8. Gosling JA, Dixon JS. Functional obstruction of the ureter and renal pelvis. A histological and electron microscopic study. *Br J Urol.* May 1978;50(3):145-52. doi:10.1111/j.1464-410x.1978.tb02790.x
9. Kang HJ, Lee HY, Jin MH, ve ark. Decreased interstitial cells of Cajal-like cells, possible cause of congenital refluxing megaureters: Histopathologic differences in refluxing and obstructive megaureters. *Urology.* Aug 2009;74(2):318-23. doi:10.1016/j.urology.2009.02.062
10. McLellan DL, Retik AB, Bauer SB, ve ark. Rate and predictors of spontaneous resolution of prenatally diagnosed primary nonrefluxing megaureter. *J Urol.* Nov 2002;168(5):2177-80; discussion 2180. doi:10.1097/01.ju.0000034943.31317.2f
11. Gokce I, Biyikli N, Tugtepe H, ve ark. Clinical spectrum of antenatally detected urinary tract abnormalities with respect to hydronephrosis at postnatal ultrasound scan. *Pediatr Surg Int.* May 2012;28(5):543-52. doi:10.1007/s00383-012-3072-z
12. Stoll C, Alembik Y, Roth MP, ve ark. Risk factors in internal urinary system malformations. *Pediatr Nephrol.* Jul 1990;4(4):319-23. doi:10.1007/BF00862508
13. Brown T, Mandell J, Lebowitz RL. Neonatal hydronephrosis in the era of sonography. *AJR Am J Roentgenol.* May 1987;148(5):959-63. doi:10.2214/ajr.148.5.959
14. Rubenwolf P, Herrmann-Nuber J, Schreckenberger M, ve ark. Primary non-refluxive megaureter in children: single-center experience and follow-up of 212 patients. *Int Urol Nephrol.* Nov 2016;48(11):1743-1749. doi:10.1007/s11255-016-1384-y
15. Dekirmendjian A, Braga LH. Primary Non-refluxing Megaureter: Analysis of Risk Factors for Spontaneous Resolution and Surgical Intervention. *Front Pediatr.* 2019 2019;7(APR):126. doi:10.3389/fped.2019.00126



16. Arena S, Magno C, Montalto AS, ve ark. Long-term follow-up of neonatally diagnosed primary megaureter: rate and predictors of spontaneous resolution. *Scand J Urol Nephrol.* Jun 2012;46(3):201-7. doi:10.3109/00365599.2012.662695
17. Braga LH, D'Cruz J, Rickard M, ve ark. The Fate of Primary Nonrefluxing Megaureter: A Prospective Outcome Analysis of the Rate of Urinary Tract Infections, Surgical Indications and Time to Resolution. *J Urol.* Apr 2016;195(4 Pt 2):1300-5. doi:10.1016/j.juro.2015.11.049
18. Di Renzo D, Aguiar L, Cascini V, ve ark. Long-term followup of primary nonrefluxing megaureter. *J Urol.* Sep 2013;190(3):1021-6. doi:10.1016/j.juro.2013.03.008
19. Gimpel C, Masioniene L, Djakovic N, ve ark. Complications and long-term outcome of primary obstructive megaureter in childhood. *Pediatr Nephrol.* Sep 2010;25(9):1679-86. doi:10.1007/s00467-010-1523-0
20. Calisti A, Oriolo L, Perrotta ML, ve ark. The fate of prenatally diagnosed primary nonrefluxing megaureter: do we have reliable predictors for spontaneous resolution? *Urology.* Aug 2008;72(2):309-12. doi:10.1016/j.urology.2008.02.032
21. Onen A, Jayanthi VR, Koff SA. Long-term followup of prenatally detected severe bilateral newborn hydronephrosis initially managed nonoperatively. *J Urol.* Sep 2002;168(3):1118-20. doi:10.1097/01.ju.0000024449.19337.8d
22. Shukla AR, Cooper J, Patel RP, ve ark. Prenatally detected primary megaureter: a role for extended followup. *J Urol.* Apr 2005;173(4):1353-6. doi:10.1097/01.ju.0000152319.72909.52
23. Ardissino G, Dacco V, Testa S, ve ark. Epidemiology of chronic renal failure in children: data from the ItalKid project. *Pediatrics.* Apr 2003;111(4 Pt 1):e382-7. doi:10.1542/peds.111.4.e382
24. Braga LH, Farokhyar F, D'Cruz J, ve ark. Risk factors for febrile urinary tract infection in children with prenatal hydronephrosis: a prospective study. *J Urol.* May 2015;193(5 Suppl):1766-71. doi:10.1016/j.juro.2014.10.091
25. Holzman SA, Braga LH, Zee RS, ve ark. Risk of urinary tract infection in patients with hydronephrosis: An analysis from the Society of Fetal Urology Prenatal Hydronephrosis Registry. *J Pediatr Urol.* Dec 2021;17(6):775-781. doi:10.1016/j.jpuro.2021.09.001
26. Ranawaka R, Hennayake S. Resolution of primary non-refluxing megaureter: an observational study. *J Pediatr Surg.* Feb 2013;48(2):380-3. doi:10.1016/j.jpedsurg.2012.11.017
27. Hodhod A, Capolicchio JP, Jednak R, ve ark. Influence of postnatal hydronephrosis in determining the need for voiding cystourethrogram in children with high-grade hydronephrosis. *Arab J Urol.* Jun 2018;16(2):238-244. doi:10.1016/j.aju.2017.11.004
28. Capolicchio JP, Braga LH, Szymanski KM. Canadian Urological Association/Pediatric Urologists of Canada guideline on the investigation and management of antenatally detected hydronephrosis. *Can Urol Assoc J.* Apr 2018;12(4):85-92. doi:10.5489/auaj.5094
29. Lee JH, Choi HS, Kim JK, ve ark. Nonrefluxing neonatal hydronephrosis and the risk of urinary tract infection. *J Urol.* Apr 2008;179(4):1524-8. doi:10.1016/j.juro.2007.11.090
30. Vereecken RL, Proesmans W. A review of ninety-two obstructive megaureters in children. *Eur Urol.* Oct 1999;36(4):342-7. doi:10.1159/000019997
31. Chertin B, Pollack A, Koulikov D, ve ark. Long-term follow up of antenatally diagnosed megaureters. *J Pediatr Urol.* Jun 2008;4(3):188-91. doi:10.1016/j.jpuro.2007.11.013
32. Davenport MT, Merquerian PA, Koyle M. Antenatally diagnosed hydronephrosis: current postnatal management. *Pediatr Surg Int.* Mar 2013;29(3):207-14. doi:10.1007/s00383-012-3258-4
33. Drlik M, Flogelova H, Martin K, ve ark. Isolated low initial differential renal function in patients with primary non-refluxing megaureter should not be considered an indication for early surgery: A multicentric study. *J Pediatr Urol.* Aug 2016;12(4):231 e1-4. doi:10.1016/j.jpuro.2016.05.025
34. de Jong TP. Treatment of the neonatal and infant megaureter in reflux, obstruction and complex congenital anomalies. *Acta Urol Belg.* Jun 1997;65(2):45-7.



35. de Kort LM, Klijn AJ, Uiterwaal CS, ve ark. Ureteral reimplantation in infants and children: effect on bladder function. *J Urol.* Jan 2002;167(1):285-7. doi:10.1097/00005392-200201000-00084
36. Aksnes G, Imaji R, Dewan PA. Primary megaureter: results of surgical treatment. *ANZ J Surg.* Dec 2002;72(12):877-80. doi:10.1046/j.1445-2197.2002.02585.x
37. Greenfield SP, Griswold JJ, Wan J. Ureteral reimplantation in infants. *J Urol.* Nov 1993;150(5 Pt 1):1460-2. doi:10.1016/s0022-5347(17)35809-3
38. Upadhyay J, Shekarriz B, Fleming P, ve ark. Ureteral reimplantation in infancy: evaluation of long-term voiding function. *J Urol.* Sep 1999;162(3 Pt 2):1209-12. doi:10.1016/S0022-5347(01)68135-7
39. Valla JS, Steyaert H, Griffin SJ, ve ark. Transvesicoscopic Cohen ureteric reimplantation for vesicoureteral reflux in children: a single-centre 5-year experience. *J Pediatr Urol.* Dec 2009;5(6):466-71. doi:10.1016/j.jpuro.2009.03.012
40. Ben-Meir D, McMullin N, Kimber C, ve ark. Reimplantation of obstructive megaureters with and without tailoring. *J Pediatr Urol.* Jun 2006;2(3):178-81. doi:10.1016/j.jpuro.2005.05.010
41. Hendren WH. Complications of Megaureter Repair in Children. *Journal of Urology.* 1975 1975;113(2):238-254. doi:10.1016/s0022-5347(17)59454-9
42. Castagnetti M, Cimador M, Sergio M, ve ark. Double-J stent insertion across vesicoureteral junction--is it a valuable initial approach in neonates and infants with severe primary non-refluxing megaureter? *Urology.* Oct 2006;68(4):870-5; discussion 875-6. doi:10.1016/j.urol.2006.05.052
43. Farrugia MK, Steinbrecher HA, Malone PS. The utilization of stents in the management of primary obstructive megaureters requiring intervention before 1 year of age. *J Pediatr Urol.* Apr 2011;7(2):198-202. doi:10.1016/j.jpuro.2010.04.015
44. Shenoy MU, Rance CH. Is there a place for the insertion of a JJ stent as a temporizing procedure for symptomatic partial congenital vesico-ureteric junction obstruction in infancy? *BJU Int.* Sep 1999;84(4):524-5. doi:10.1046/j.1464-410x.1999.00256.x
45. Doudt AD, Pusateri CR, Christman MS. Endoscopic Management of Primary Obstructive Megaureter: A Systematic Review. *J Endourol.* Jun 2018;32(6):482-487. doi:10.1089/end.2017.0434
46. Barbancho DC, Fraile AG, Sánchez RT, ve ark. [Is effective the initial management of primary nonrefluxing megaureter with double-J stent?]. *Cirugia Pediatrica : Organo Oficial de la Sociedad Espanola de Cirugia Pediatrica.* 2008-01-01 2008;21(1):32-36.
47. Carroll D, Chandran H, Joshi A, ve ark. Endoscopic placement of double-J ureteric stents in children as a treatment for primary obstructive megaureter. *Urol Ann.* Sep 2010;2(3):114-8. doi:10.4103/0974-7796.68860
48. Angerri O, Caffaratti J, Garat JM, ve ark. Primary obstructive megaureter: initial experience with endoscopic dilatation. *J Endourol.* Sep 2007;21(9):999-1004. doi:10.1089/end.2006.0122
49. Garcia-Aparicio L, Rodo J, Krauel L, ve ark. High pressure balloon dilation of the uretero-vesical junction--first line approach to treat primary obstructive megaureter? *J Urol.* May 2012;187(5):1834-8. doi:10.1016/j.juro.2011.12.098
50. Kajbafzadeh AM, Payabvash S, Salmasi AH, ve ark. Endoureterotomy for treatment of primary obstructive megaureter in children. *J Endourol.* Jul 2007;21(7):743-9. doi:10.1089/end.2006.0330
51. Rabinowitz R, Barkin M, Schillinger JF, ve ark. Surgical treatment of the massively dilated ureter in children. Part I. management by cutaneous ureterostomy. *J Urol.* May 1977;117(5):658-62. doi:10.1016/s0022-5347(17)58576-6
52. Álvarez N, García-Núñez B, Esteva C, ve ark. Antegrade endoscopic dilatation as an alternative approach to primary obstructive megaureter. *Cirugia pediatrica : organo oficial de la Sociedad Espanola de Cirugia Pediatrica.* 2021-04-01 2021;34(2):100-104.



53. Trobs RB, Heinecke K, Elouahidi T, ve ark. Renal function and urine drainage after conservative or operative treatment of primary (obstructive) megaureter in infants and children. *Int Urol Nephrol*. 2006-02 2006;38(1):141-7. doi:10.1007/s11255-005-3615-5
54. Kitchens DM, DeFoor W, Minevich E, ve ark. End cutaneous ureterostomy for the management of severe hydronephrosis. *J Urol*. Apr 2007;177(4):1501-4. doi:10.1016/j.juro.2006.11.076
55. Kogan BA, Gohary MA. Cutaneous Ureterostomy as a Permanent External Urinary Diversion in Children. *Journal of Urology*. 1984 1984;132(4):729-731. doi:10.1016/s0022-5347(17)49844-2
56. MacGregor PS, Kay R, Straffon RA. Cutaneous ureterostomy in children--long-term followup. *J Urol*. Sep 1985;134(3):518-20. doi:10.1016/s0022-5347(17)47271-5
57. Sarduy GS, Crooks KK, Smith JP, ve ark. Results in children managed by cutaneous ureterostomy. *Urology*. May 1982;19(5):486-8. doi:10.1016/0090-4295(82)90604-5
58. Lee SD, Akbal C, Kaefer M. Refluxing ureteral reimplant as temporary treatment of obstructive megaureter in neonate and infant. *J Urol*. Apr 2005;173(4):1357-60; discussion 1360. doi:10.1097/01.ju.0000152317.72166.df
59. Babu R. 'Mini reimplantation' for the management of primary obstructed megaureter. *J Pediatr Urol*. Apr 2016;12(2):103 e1-4. doi:10.1016/j.jpuro.2015.08.017
60. Kaefer M, Misseri R, Frank E, ve ark. Refluxing ureteral reimplantation: a logical method for managing neonatal UVJ obstruction. *J Pediatr Urol*. Oct 2014;10(5):824-30. doi:10.1016/j.jpuro.2014.01.027
61. Paquin AJ, Jr. Ureterovesical anastomosis: the description and evaluation of a technique. *J Urol*. Nov 1959;82(5):573-83. doi:10.1016/s0022-5347(17)65934-2
62. Starr A. Ureteral plication. A new concept in ureteral tailoring for megaureter. *Invest Urol*. Sep 1979;17(2):153-8.
63. Kaliciński ZH, Kansy J, Kotarbińska B, ve ark. Surgery of megaureters—Modification of Hendren's operation. *Journal of Pediatric Surgery*. 1977 1977;12(2):183-188. doi:10.1016/s0022-3468(77)80005-5
64. McCool AC, Perez LM, Joseph DB. Contralateral vesicoureteral reflux after simple and tapered unilateral ureteroneocystostomy revisited. *J Urol*. Sep 1997;158(3 Pt 2):1219-20. doi:10.1097/00005392-199709000-00142
65. Lavine MA, Siddiq FM, Cahn DJ, ve ark. Vesicoureteral reflux after ureteroneocystostomy: indications for postoperative voiding cystography. *Tech Urol*. Mar 2001;7(1):50-4.
66. Caione P, Capozza N, Asili L, ve ark. Is primary obstructive megaureter repair at risk for contralateral reflux? *J Urol*. Sep 2000;164(3 Pt 2):1061-3. doi:10.1097/00005392-200009020-00034
67. Neeman BB, Jaber J, Kocherov S, ve ark. Does Renal Function Remain Stable after Puberty in Children who underwent Ureteral Reimplantation due to Ureterovesical Junction Obstruction? *Eur J Pediatr Surg*. Apr 2021;31(2):187-190. doi:10.1055/s-0040-1712172