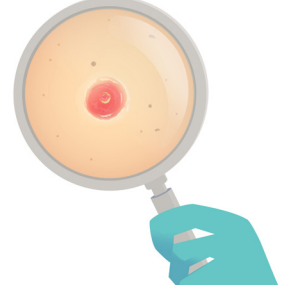


## BÖLÜM 29

# PRİMER KUTANÖZ ADENOİD KİSTİK KARSİNOM



Zeynep TOSUNER<sup>1</sup>

### GİRİŞ

Derinin adenoid kistik karsinomu (AKK) nadir görülen kötü huylu bir neoplazmdir (1). Adenoid kistik karsinomlara çoğunlukla tükürük bezi, bronşlar, meme, özofagus, lakrimal bez, serüminöz bez, serviks, vulva ve prostatta rastlanır (2, 3).

### KLİNİK

Genellikle orta-ileri yaşlarda (60 yaş) civarında tanı alır. Tanıdan önce birkaç yıl boyunca mevcut olan boyutları 0,5-8 cm arasında değişen tek bir nodül olarak görülür. Nadiren ağrı ve kanama bildirilmiştir. En sık görüldüğü yer kafa derisidir. Gövde, özellikle göğüs duvarı ve karın diğer sık görülen lokalizasyonlardır (4). Bartholin bezi kaynaklı lezyonlar vulvada kitle olarak ortaya çıkar (5). Seruminöz bez kaynaklı olanlar dış kulak yolunda gelişir (6). Nadiren ektojik lakrimal gland kaynaklı AKK görülebildiği bildirilmiştir(7). Perineal yayılım nadir görülür (8).

### HİSTOPATOLOJİK BULGULAR

Tükürük bezinin AKK'unda olduğu gibi, tek veya daha sık kombinasyon halinde üç ana büyüme paterni, kribriform, tübüler ve solid paternlerdir(**Resim 1**). En yaygın

<sup>1</sup> Uzm. Dr., Acıbadem Üniversitesi, Tıp Fakültesi, Tıbbi Patoloji AD., zeyneptosuner@yahoo.com.tr



## KAYNAKLAR

1. Dores GM, Huycke MM, Devesa SS, Garcia CA. Primary cutaneous adenoid cystic carcinoma in the United States: incidence, survival, and associated cancers, 1976 to 2005. *J Am Acad Dermatol* 2010; 63: 71-78.
2. Salzman MJ, Eades E. Primary cutaneous adenoid cystic carcinoma: a case report and review of the literature. *Plast Reconstr Surg* 1991; 88: 140-144.
3. Elder D, Massi D, Scolyer R, Willemze R. WHO Classification of Skin Tumours 2018
4. Kato N, Yasukawa K, Onozuka T. Primary cutaneous adenoid cystic carcinoma with lymph node metastasis. *Am J Dermatopathol* 1998; 20: 571-577.
5. Woida FM, Ribeiro-Silva A. Adenoid cystic carcinoma of the Bartholin gland: an overview. *Arch Pathol Lab Med* 2007; 131: 796-798.
6. Perzin KH, Gullane P, Conley J. Adenoid cystic carcinoma involving the external auditory canal. A clinicopathologic study of 16 cases. *Cancer* 1982; 50: 2873-2883.
7. Weis E, Rootman J, Joly TJ et al. Epithelial lacrimal gland tumors: pathologic classification and current understanding. *Arch Ophthalmol* 2009; 127: 1016-1028.
8. Numajiri T, Nishino K, Uenaka M. Giant primary cutaneous adenoid cystic carcinoma of the perineum: histological and radiological correlations. *Acta Derm Venereol* 2008; 88: 316-318.
9. Kazakov DV, Michal M, Kacerovska D, McKee P. Cutaneous Adnexal Tumors. Wolters Kluwer Health | Lippincott Williams & Wilkins, 2012.
10. Bergman R, Lichtig C, Moscona RA, Friedman-Birnbaum R. A comparative immunohistochemical study of adenoid cystic carcinoma of the skin and salivary glands. *Am J Dermatopathol* 1991; 13: 162-168.
11. North JP, McCalmont TH, Fehr A et al. Detection of MYB Alterations and Other Immunohistochemical Markers in Primary Cutaneous Adenoid Cystic Carcinoma. *Am J Surg Pathol* 2015; 39: 1347-1356.
12. Evangelista MT, North JP. MYB, CD117 and SOX-10 expression in cutaneous adnexal tumors. *J Cutan Pathol* 2017; 44: 444-450.
13. Wick MR, Swanson PE. Primary adenoid cystic carcinoma of the skin. A clinical, histological, and immunocytochemical comparison with adenoid cystic carcinoma of salivary glands and adenoid basal cell carcinoma. *Am J Dermatopathol* 1986; 8: 2-13.
14. Bishop JA, Taube JM, Su A et al. Secretory Carcinoma of the Skin Harboring ETV6 Gene Fusions: A Cutaneous Analogue to Secretory Carcinomas of the Breast and Salivary Glands. *Am J Surg Pathol* 2017; 41: 62-66.
15. Abiola OO, Ano-Edward GH, Oluwumi OA, Lasisi ME. Primary cutaneous mucinous carcinoma of the scrotum: A rare tumor at a rare site - A case report and review of literature. *Urol Ann* 2020; 12: 83-86.
16. Rutten A, Kutzner H, Mentzel T et al. Primary cutaneous cribriform apocrine carcinoma: a clinicopathologic and immunohistochemical study of 26 cases of an under-recognized cutaneous adnexal neoplasm. *J Am Acad Dermatol* 2009; 61: 644-651.
17. Petersson F, Kutzner H, Spagnolo DV et al. Adenoid cystic carcinoma-like pattern in spiradenoma and spiradenocylindroma: a rare feature in sporadic neoplasms and those associated with Brooke-Spiegler syndrome. *Am J Dermatopathol* 2009; 31: 642-648.
18. Chang CH, Liao YL, Hong HS. Cutaneous metastasis from adenoid cystic carcinoma of the parotid gland. *Dermatol Surg* 2003; 29: 775-779.
19. Kazakov DV, Spagnolo DV, Kacerovska D, Michal M. Lesions of anogenital mammary-like glands: an update. *Adv Anat Pathol* 2011; 18: 1-28.
20. Prieto-Granada CN, Zhang L, Antonescu CR et al. Primary cutaneous adenoid cystic carcinoma with MYB aberrations: report of three cases and comprehensive review of the literature. *J Cutan Pathol* 2017; 44: 201-209.
21. Seab JA, Graham JH. Primary cutaneous adenoid cystic carcinoma. *J Am Acad Dermatol* 1987; 17: 113-118.
22. Ramakrishnan R, Chaudhry IH, Ramdial P et al. Primary cutaneous adenoid cystic carcinoma: a clinicopathologic and immunohistochemical study of 27 cases. *Am J Surg Pathol* 2013; 37: 1603-1611.
23. Lang PG, Jr., Metcalf JS, Maize JC. Recurrent adenoid cystic carcinoma of the skin managed by microscopically controlled surgery (Mohs surgery). *J Dermatol Surg Oncol* 1986; 12: 395-398.