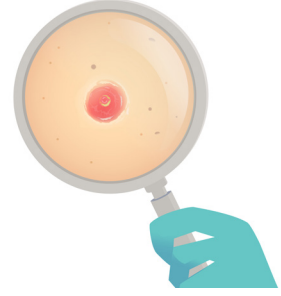


# BÖLÜM 6

## PİLOMATRIKSOMA



*Fatma Gülçiçek AYRANCI<sup>1</sup>*

### GİRİŞ

Pilomatiksoma, pilomatikoma, Malherbe tümörü, Malherbe'in kalsifiye olan epiteliyoması aynı tümörün farklı isimleri olarak karşımıza çıkar (1). İlk olarak 1880'de Malherbe ve Chenantis tarafından tanımlanmıştır (2).

Pilomatiksoma benign bir deri eki tümörü olup, deri eki tümörlerinin "kıl folikül kaynaklı" grubu içerisinde yer alır (3) ve kıl folikülü matrisinden köken aldığı kabul edilmektedir. Tümör hücreleri kıl matrisi, kıl korteksi, foliküler infundibulum, iç ve dış kök kılıfı ve kıl kabarıklığına diferansiye olabilmektedir (4).

### EPİDEMİYOLOLOJİ

Pilomatiksomanın görülme yaşı bimodal dağılım gösterir; 10 yaş altı küçük çocuklar ve 50 yaş üzeri yetişkinler olmak üzere 2 farklı yaş grubunda daha sık görülme eğilimindedir. Olguların %90'ı, 10 yaş ve altı çocuklardır. Ortalama yaş 4,5 olarak bildirilmiştir (5).

Pilomatiksomalara daha çok baş boyunda ve saçlı deride görülür. Ekstremiteler ve gövdede daha az görülebilir. Nadiren periorbital bölgede, skrotum ve vulva-

<sup>1</sup> Uzm. Dr., Sağlık Bilimleri Üniversitesi Ümraniye Eğitim ve Araştırma Hastanesi, Patoloji Kliniği, gulcicek.ayranci@gmail.com



## KAYNAKLAR

1. Le C, Bedocs PM. Calcifying Epithelioma of Malherbe. *StatPearls*. Treasure Island (FL): StatPearls Publishing; 2022. <http://www.ncbi.nlm.nih.gov/books/NBK493165/>
2. King ICC, Rahman KMA, Henderson A, et al. Multiple Familial Pilomatrixomas in Three Generations: An Unusual Clinical Picture. *Pediatric Dermatology*. 2015;32(1): 97–101. doi:10.1111/pde.12353
3. Brownstein MH, Shapiro L. The pilosebaceous tumors. *International Journal of Dermatology*. 1977;16(5): 340–352. doi:10.1111/j.1365-4362.1977.tb00750.x
4. Stewart C, Novoa R, Seykora J. Chapter 30: Tumors of the Epidermal Appendages. *Lever's Histopathology of the Skin*. 11th ed. Philadelphia, PA: Wolters Kluwer; 2015.
5. Duflo S, Nicollas R, Roman S, et al. Pilomatrixoma of the head and neck in children: a study of 38 cases and a review of the literature. *Archives of Otolaryngology–Head & Neck Surgery*. 1998;124(11): 1239–1242. doi:10.1001/archotol.124.11.1239
6. Pinheiro TN, Fayad FT, Arantes P, et al. A new case of the pilomatrixoma rare in the preauricular region and review of series of cases. *Oral and Maxillofacial Surgery*. 2018;22(4): 483–488. doi:10.1007/s10006-018-0724-8
7. Guinot-Moya R, Valmaseda-Castellon E, Berini-Aytes L, et al. Pilomatrixoma. Review of 205 cases. *Medicina Oral, Patología Oral Y Cirugía Bucal*. 2011;16(4): e552-555. doi:10.4317/medoral.16.e552
8. Patterson JW. Chapter 19 : Cutaneous Appendageal Tumors. *Practical Skin Pathology: A Diagnostic Approach*. 1st ed. Philadelphia, PA: Elsevier; 2013. p. 357–400.
9. Gongidi P, Meshekow J, Holdbrook T, et al. Giant pilomatrixoma presenting in the posterior thorax, a rare location and the largest described. *Case Reports in Radiology*. 2015;2015: 590742. doi:10.1155/2015/590742
10. Pant I, Joshi SC, Kaur G, et al. Pilomatricoma as a diagnostic pitfall in clinical practice: report of two cases and review of literature. *Indian Journal of Dermatology*. 2010;55(4): 390–392. doi:10.4103/0019-5154.74566
11. Rübben A, Wahl RU, Eggermann T, et al. Mutation analysis of multiple pilomatricomas in a patient with myotonic dystrophy type 1 suggests a DM1-associated hypermutation phenotype. *PLoS One*. 2020;15(3): e0230003. doi:10.1371/journal.pone.0230003
12. Trufant J, Kurz W, Frankel A, et al. Familial multiple pilomatrixomas as a presentation of attenuated adenomatosis polyposis coli. *Journal of Cutaneous Pathology*. 2012;39(4): 440–443. doi:10.1111/j.1600-0560.2011.01836.x
13. Mesa-Álvarez L, Batalla A, Iglesias-Puzas Á, et al. Multiple Pilomatricomas: A Retrospective Study and Literature Review. *The American Journal of Dermatopathology*. 2019;41(4): 293–295. doi:10.1097/DAD.0000000000001296
14. Maeda D, Kubo T, Miwa H, et al. Multiple pilomatricomas in a patient with Turner syndrome. *The Journal of Dermatology*. 2014;41(6): 563–564. doi:10.1111/1346-8138.12509
15. Matsuura H, Hatamochi A, Nakamura Y, et al. Multiple pilomatricoma in trisomy 9. *Dermatology (Basel, Switzerland)*. 2002;204(1): 82–83. doi:10.1159/000051819
16. Bernier F-E, Schreiber A, Coulombe J, et al. Pilomatricoma Associated with Kabuki Syndrome. *Pediatric Dermatology*. 2017;34(1): e26–e27. doi:10.1111/pde.13014
17. Gilaberte Y, Ferrer-Lozano M, Oliván MJ, et al. Multiple giant pilomatricoma in familial Sotos syndrome. *Pediatric Dermatology*. 2008;25(1): 122–125. doi:10.1111/j.1525-1470.2007.00602.x
18. Minai L, Yagasaki H, Ogawa Y, et al. Multiple bullous pilomatricomas in a patient with Rubinstein-Taybi syndrome. *The Journal of Dermatology*. 2021;48(9): e482–e483. doi:10.1111/1346-8138.16030



19. Resende CIP, Gomes J, Duarte M da L, et al. Giant pilomatricoma in a patient with tuberous sclerosis, both diagnosed in the adult life. *BMJ case reports*. 2013;2013: bcr2013010382. doi:10.1136/bcr-2013-010382
20. Ciriacks K, Knabel D, Waite MB. Syndromes associated with multiple pilomatricomas: When should clinicians be concerned? *Pediatric Dermatology*. 2020;37(1): 9–17. doi:10.1111/pde.13947
21. Nakamura T. Shadow Cell Differentiation: A Comparative Analysis of Modes of Cell Death with Apoptosis and Epidermal/Trichilemmal Keratinization. *Dermatopathology*. 2018;5(3): 86–97. doi:10.1159/000490491
22. Alli N, Güngör E, Artüz F. Perforating pilomatricoma. *Journal of the American Academy of Dermatology*. 1996;35(1): 116–118. doi:10.1016/s0190-9622(96)90523-x
23. Vázquez-Osorio I, García SM, Rodríguez-Díaz E, et al. Anetodermic pilomatricoma: clinical, histopathologic, and sonographic findings. *Dermatology Online Journal*. 2017;23(3): 13030/qt5920j4zm.
24. Kaddu S, Soyer HP, Wolf IH, et al. Proliferating pilomatricoma. A histopathologic simulator of matrical carcinoma. *Journal of Cutaneous Pathology*. 1997;24(4): 228–234. doi:10.1111/j.1600-0560.1997.tb01586.x
25. Tsunoda K, Arakawa N, Akasaka T. A case of pigmented pilomatricoma (calcifying epithelioma): the role of mast cells in pigmentation. *European journal of dermatology: EJD*. 2016;26(3): 308–309. doi:10.1684/ejd.2016.2746
26. Sung K-Y, Lee S, Jeong Y, et al. Pseudocystic pilomatricoma: A new variant and review of the literature. *The Australasian Journal of Dermatology*. 2021;62(1): 60–63. doi:10.1111/ajd.13402
27. Torun N, Canbolat ET. Aggressive metastatic malignant pilomatrixoma followed by 18F-FDG PET/CT. *Revista Espanola De Medicina Nuclear E Imagen Molecular*. 2019;38(4): 254–255. doi:10.1016/j.remnm.2018.07.002
28. Do JE, Noh S, Jee HJ, et al. Familial multiple pilomatricomas showing clinical features of a giant mass without associated diseases: Correspondence. *International Journal of Dermatology*. 2013;52(2): 250–252. doi:10.1111/j.1365-4632.2010.04867.x
29. Jaiswal AA, Garg AK, Membally R, et al. Ossifying pilomatrixoma with marrow formation of the left cheek region – Case report with review of literature. *Egyptian Journal of Ear, Nose, Throat and Allied Sciences*. 2015;16(2): 193–199. doi:10.1016/j.ejenta.2015.02.002
30. Kim YS, Shin DH, Choi JS, et al. The Immunohistochemical Patterns of the beta-Catenin Expression in Pilomatricoma. *Annals of Dermatology*. 2010;22(3): 284–289. doi:10.5021/ad.2010.22.3.284
31. Xu X, Lyle S, Liu Y, et al. Differential expression of cyclin D1 in the human hair follicle. *The American Journal of Pathology*. 2003;163(3): 969–978. doi:10.1016/S0002-9440(10)63456-6
32. Patterson J. Chapter 34: Tumors of cutaneous appendages. *Weedon's Skin Pathology*. 5th ed. Amsterdam: Elsevier; 2021. p. 952–1015.
33. Rumayor A, Carlos R, Kirsch HM, et al. Ghost cells in pilomatrixoma, craniopharyngioma, and calcifying cystic odontogenic tumor: histological, immunohistochemical, and ultrastructural study. *Journal of Oral Pathology & Medicine: Official Publication of the International Association of Oral Pathologists and the American Academy of Oral Pathology*. 2015;44(4): 284–290. doi:10.1111/jop.12234



34. Mitteldorf CAT da S, Vilela RS, Fugimori ML, et al. Novel Mutations in Pilomatrixoma, CTN-NB1 p.s45F, and FGFR2 p.s252L: A Report of Three Cases Diagnosed by Fine-Needle Aspiration Biopsy, with Review of the Literature. *Case Reports in Genetics*. 2020;2020: 8831006. doi:10.1155/2020/8831006
35. Plotzke JM, Adams DJ, Harms PW. Molecular pathology of skin adnexal tumours. *Histopathology*. 2022;80(1): 166–183. doi:10.1111/his.14441
36. Wachter-Giner T, Bieber I, Warmuth-Metz M, et al. Multiple pilomatricomas and gliomatosis cerebri—a new association? *Pediatric Dermatology*. 2009;26(1): 75–78. doi:10.1111/j.1525-1470.2008.00827.x
37. Jones CD, Ho W, Robertson BF, et al. Pilomatrixoma: A Comprehensive Review of the Literature. *The American Journal of Dermatopathology*. 2018;40(9): 631–641. doi:10.1097/DAD.0000000000001118
38. Richet C, Maza A, Dreyfus I, et al. Childhood pilomatricomas: Associated anomalies. *Pediatric Dermatology*. 2018;35(5): 548–551. doi:10.1111/pde.13564
39. Melancon JM, Tom WL, Lee RA, et al. Management of pilomatrix carcinoma: a case report of successful treatment with Mohs micrographic surgery and review of the literature. *Dermatologic Surgery: Official Publication for American Society for Dermatologic Surgery [et Al.]*. 2011;37(12): 1798–1805. doi:10.1111/j.1524-4725.2011.02170.x
40. Sherrod QJ, Chiu MW, Gutierrez M. Multiple pilomatricomas: cutaneous marker for myotonic dystrophy. *Dermatology Online Journal*. 2008;14(7): 22.
41. Ackerman AB, Reddy VB, Soyer HP. *Neoplasms with Follicular Differentiation*. 2nd ed. Kingsport, Tenn: Ardor Scribendi; 2001. 1109 p.
42. Chen W-S, Juan C-K, Chen Y-J, et al. Melanocytic matricoma: A new case with literature review. *Dermatologica Sinica*. 2018;36(4): 238–239. doi:10.1016/j.dsi.2018.04.003
43. Hardisson D, Linares MD, Cuevas-Santos J, et al. Pilomatrix Carcinoma: A Clinicopathologic Study of Six Cases and Review of the Literature: *The American Journal of Dermatopathology*. 2001;23(5): 394–401. doi:10.1097/00000372-200110000-00002
44. Papadakis M, de Bree E, Floros N, et al. Pilomatrix carcinoma: More malignant biological behavior than was considered in the past. *Molecular and Clinical Oncology*. 2017;6(3): 415–418. doi:10.3892/mco.2017.1148
45. Yeo M-K, Bae GE. Comparison of Benign and Malignant Pilomatricomas Using Whole-exome Sequencing. *Cancer Genomics & Proteomics*. 2020;17(6): 795–802. doi:10.21873/cgp.20233
46. Nigam JS, Singh S. Fine-needle aspiration cytology of pilomatrixoma: A short series of three cases. *CytoJournal*. 2014;11: 30. doi:10.4103/1742-6413.144689
47. Viswanathan K, Sung SJ, Scognamiglio T, et al. Fine needle aspiration of pilomatrixoma: Cytologic features on thinprep and diagnostic pitfalls. *Diagnostic Cytopathology*. 2018;46(5): 452–455. doi:10.1002/dc.23909
48. Bharani V, Kumar R, Gupta N, et al. Fine-needle aspiration cytology in primary cutaneous tumors: BHARANI et al. *Diagnostic Cytopathology*. 2017;45(8): 681–688. doi:10.1002/dc.23741
49. Bollu BK, Collin M, Shun A. Minimally invasive surgical treatment of pilomatrixoma. *ANZ Journal of Surgery*. 2021;91(10): 2126–2129. doi:10.1111/ans.16521