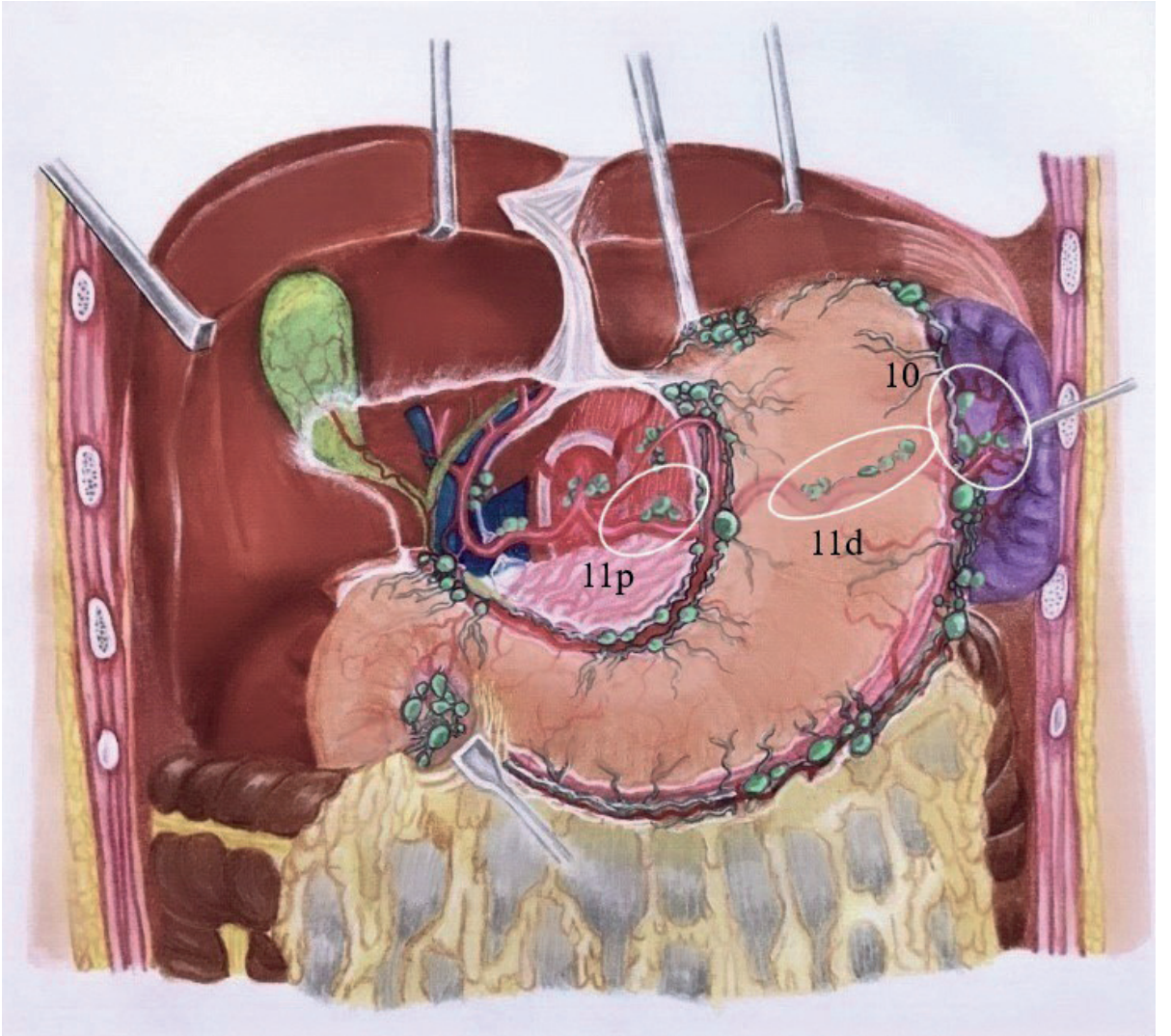


Konu  
**7**

## Splenik Arter ve Splenik Hilus Diseksiyonu (11, 10)

Dr. Ebru ESEN, Dr. Ali Ekrem ÜNAL



**Şekil 1:** 11 ve 10 nolu lenf nodu istasyonları.

## Kaynaklar

1. Shimada Y. JGCA (The Japan Gastric Cancer Association). Gastric cancer treatment guidelines. *Jpn J Clin Oncol.* 2004 Jan;34(1):58.
2. Kawamura H1, Homma S, Yokota R et al. Inspection of safety and accuracy of D2 lymph node dissection in laparoscopy-assisted distal gastrectomy. *World J Surg.* 2008 Nov;32(11):2366-70. doi: 10.1007/s00268-008-9697-3. Epub 2008 Jul 31.
3. Satoh S, Okabe H, Kondo K et al. A novel laparoscopic approach for safe and simplified suprapancreatic lymph node dissection of gastric cancer. *Surg Endosc.* 2009 Feb;23(2):436-7. doi: 10.1007/s00464-008-9978-9. Epub 2008 Jun 5.
4. Japanese Gastric Cancer Association. Japanese classification of gastric carcinoma: 3rd English edition. *Gastric Cancer.* 2011 Jun;14(2):101-12. doi: 10.1007/s10120-011-0041-5.
5. Fukunaga T, Hiki N, Tokunaga M et al. Left-sided approach for suprapancreatic lymph node dissection in laparoscopy-assisted distal gastrectomy without duodenal transection. *Gastric Cancer.* 2009;12(2):106-12. doi: 10.1007/s10120-009-0508-9. Epub 2009 Jun 27.
6. Huang CM, Chen QY, Lin JX et al. Huang's three-step maneuver for laparoscopic spleen-preserving No. 10 lymph node dissection for advanced proximal gastric cancer. *Chin J Cancer Res.* 2014 Apr;26(2):208-10. doi: 10.3978/j.issn.1000-9604.2014.04.05.