

Bölüm 17

ÖSTAKİ TÜPÜ VE SERÖZ OTİTİS MEDIA

Sercan ÇIKRIKCI¹

GİRİŞ

Seröz otitis media, çocukluk çağında çok sık görülmesi nedeniyle orta kulak patolojileri içinde ayrı bir öneme sahiptir. Ayrıca, orta kulağın normal bir şekilde çalışabilmesi için sağlıklı bir östaki tüpü gereklidir.

1.ÖSTAKİ TÜPÜ

Östaki tüpü, orta kulak boşluğundan başlayıp nazofarenkste alt konkanın arka ucuna uzanır ve adenoid doku yatağının lateralinde nazofarenkse açılır. Orta kulak ve mastoidin dışarıya açılmasını sağlayan ve üzerinde birçok çalışma bulunan anatomik bir yapıdır.

Bartholomaeus Eustachius (1520-1574) östaki tüpünün ilk tarif eden kişi olarak tanınır. Antonio Maria Valsalva (1666-1723) östaki tüpünün fonksiyonu ile birlikte tanımını yapmış ve bu yapıya ‘Tuba Eustachii’ adını vermiştir (1).

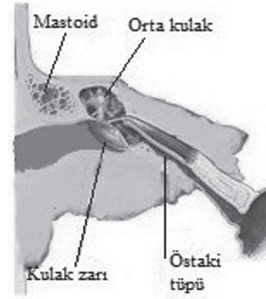
1-1. Embriyolojisi

Östaki tüpü, embriyolojik gelişiminde endoderm ile dōşeli olan birinci faringeal cepten köken alır. Fetusta östaki tüpünün esas gelişimi fetal dönemin 16. ve 28. haftaları arasında olmakta ve bu dönemde kartilaj kısmın lümeninin gelişimi büyük oranda tamamlamaktadır (2).

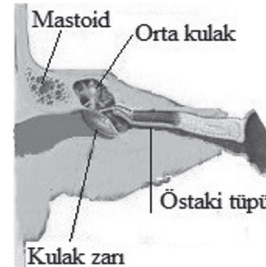
1-2. Anatomisi

Östaki tüpü; orta kulaktan nazofarenkse açılan, posterolateral kısmı kemik doku içerisinde,

anteromedial bölümü ise fibrokartilojenöz olan 2 farklı bölümden oluşan tüp şeklinde bir yapıdır. Kemik bölümü temporal kemiğin petröz kısmında bulunur. Fibrokartilojenöz kısmı da esnek bağ dokusu ve kıkırdaktan oluşur. Aktif olarak çalışan kısım fibrokartilojenöz kısmıdır. Bu kısım kafatası tabanına ligamentlerle bağlıdır. Östaki tüpünün toplam uzunluğu yeni doğanlarda 17-18mm iken, erişkinlerde 32-44mm arasında değişmektedir (3,4). Horizontal planda yeni doğanlarda 10 derece, erişkinlerde 30-40 derece açı yapar ve bu açı sağ tarafta sola göre daha dardır (Şekil 1 ve 2) (5,6).



Şekil 1: Östaki tüpü erişkin anatomisi



Şekil 2: Östaki tüpü çocuk anatomisi

ya da hastalığa bağlı olarak da bazı komplikasyonlar gelişebilir.

Ventilasyon tüpünün komplikasyonları :

- Otore
- Granülom
- Tüplerin erken atılması
- Tüplerin orta kulağa göçü
- Kalıcı perforasyon
- Miringoskleroz
- İatrojenik kolesteatom (58,95)

Ventilasyon tüpü çıktıktan sonra hastalar düzenli olarak takip edilmelidir. Bu hastalarda SOM tekrarlayabilir. Ventilasyon tüplerinin kalma süresinin ne kadar kısa olursa, rekürrens oranının o kadar yüksek olduğunu gösteren yayınlar mevcuttur. SOM tedavisi için ideal tüpler, en düşük komplikasyona ve tekrarlama oranına sahip olmalıdır (96). SOM nüksü için en önemli faktör: ventilasyon tüpü yerleştirilmesi sırasındaki yaş ve tüpün kalma süresidir. 48 ayın altındaki çocuklarda ve ventilasyon tüpü kalma süresi 9 ay altında olması durumunda nüks artmaktadır (97). Alerji, gastroözefageal reflü, prematürite veya pasif sigara öyküsünün olmasının nüks ile anlamlı bir ilişki tespit edilememiştir (97).

SONUÇ

Östaki tüpü, orta kulak ve mastoidin gelişimi, havalanması ve fonksiyonlarını yerine getirmesi için önemli görevler üstlenmektedir. Ayrıca kronik otitis media cerrahisinin başarısı için de gerekli faktörlerden birisidir. Östaki tüpü patolojileri seröz otitis mediaya neden olmaktadır. Seröz otitis media çocukluk çağda çok sık görülen, işitme kaybına neden olarak çocuğun gelişimini ve okul başarısını etkileyen bir hastalıktır. Bu hastalar sık takip edilmeli ve uygun tedavisi düzenlenmelidir.

Referanslar

1. Shampo MA, Kyle RA. Bartolomeo eustachi. JAMA 1981;246(22): 2596.
2. Swarts JD,Rood SR, Doyle WJ: Fetal development of the auditory tube and paratubal musculature. Cleft Palate J 1986, 23(4):289-311.
3. Proctor B. Embryology and anatomy of the Eustachian tube. Arch otolaryngology 1967;86:503-14
4. Zöllner F. Anatomie, Physiologie und Klinik der Ohrtrompete und ihre Diagnostisch-Therapeutischen Beziehungen zu allen Nachbarschafterkrankungen. In: Zange J, editör. Hals-, Nasen-, Ohrenheilkunde der Gegenwart und ihre Grenzgebiete. Berlin: Springer; 1942. P . 1-213.
5. Seibert JW, Danner CJ. Eustachian tube function and the middle ear. Otolaryngol Clin North Am. 2006 Dec;39(6):1221-35.
6. Pahnke J. Morphology, function and clinical aspect of the Eustachian tube. In: Klaus Jahnke, editör. Middle Ear Surgery. Recent Advances and Future Directions. Stuttgart: Georg Thieme Verlag; 2004.p 23-32.
7. Bluestone CD: Anatomy and Physiology of the Eustachian Tube. In: Cummings CW, Fredrickson JM, Haliker LA, Krause CJ, Richardson MA, Schüller DE (eds): Cummings Otolaryngology Head and Neck Surgery, Vol 4, 3rd ed. Missouri, Mosby-Year Book, 1998, p:3003-3025.
8. Poe DS, Metson RB, Kujawski O. Laser eustachian tuboplasty: a preliminary report. Laryngoscope 2003;113:583-91.
9. Pöyhönen L, Kivekäs I, Silvola J, Poe D, Rautiainen M. Mucociliary function of the eustachian tube in the eustachian tube dysfunction. Acta Otolaryngol. 2019 Mar;139(3):238-242.
10. Mitchell GAC: The autonomic nerve supply of the throat, nose and ear. J Laryngol Otol 1954, 68:495.
11. Nathanson SE, Jackson RT: Vidian nerve and the eustachian tube. Ann Otol Rhinol Laryngol 1976;85:83.
12. Dinç AE, Damar M, Uğur MB, Öz II, Eliçora SŞ, Bişkin S, Tutar H. Do the angle and length of the eustachian tube influence the development of chronic otitis media?. Laryngoscope. 2015 Sep;125(9):2187-92.
13. Suzuki C, Sando I, Balaban CD, Kitagawa M, Takasaki K. Difference in attachment of the tensor veli palatini muscle to the eustachian tube cartilage with age. Ann Otol Rhinol Laryngol. 2003 May;112(5):439-43.
14. Hong J, Chen K, Lyu H, Yin D, Yang L, Zhang T, Dai P. Age-related changes in the morphological relationship between the supratubal recess and the Eustachian tube. Auris Nasus Larynx. 2018 Feb;45(1):88-95.
15. Orita Y, Sando I, Hasebe S, Miura M. Postnatal change on the location of Ostmann's fatty tissue in the region lateral to Eustachian tube. Int J Pediatr Otorhinolaryngol. 2003 Oct;67(10):1105-12.
16. Orita Y, Sando I, Hirsch BE, Miura M, Hasebe S, Balaban CD. Postnatal development of the eustachian tube glands. Laryngoscope. 2002 Sep;112(9):1647-52.
17. Yamaguchi N, Sando I, Hashida Y, Takahashi H, Matsune S. Histologic study of eustachian tube cartilage with and without congenital anomalies: a preliminary study. Ann Otol Rhinol Laryngol. 1990 Dec;99(12):984-7.
18. Noonan KY, Linthicum FH, Lopez IA, Ishiyama A, Miller ME. A Histopathologic Comparison of Eustachian Tube Anatomy in Pediatric and Adult Temporal Bones. Otol Neurotol. 2019 Mar;40(3):e233-e239.
19. Lükens A , Dimartino E , Günther RW , Krombach GA. Functional MR imaging of the eustachian tube in patients with clinically proven dysfunction: correlation with lesions detected on MR images. Eur Radiol. 2012 Mar;22(3):533-8
20. Sanjana Vijay Nemade, Kiran Jaywant Shinde, Varsha P.Rangankar, Priya Bhole. Evaluation and significance of Eustachian tube angles and pretympenic diameter in

- HRCT temporal bone of patients with chronic otitis media. *World Journal of Otorhinolaryngology - Head and Neck Surgery* Volume 4, Issue 4, December 2018, Pages 240-245
21. Aksoy S, Sayin I, Yazici ZM, et al. The evaluation of the angles of Eustachian tubes in the patients with chronic otitis media on the temporal computerized tomography. *Niger J Clin Pract.* 2016;19:318e322.
 22. Takasaki K, Takahashi H, Miyamoto I, et al. Measurement of angle and length of the eustachian tube on computed tomography using the multiplanar reconstruction technique. *Laryngoscope.* 2007;117:1251e1254.
 23. Schuon R, Mrevlje B, Vollmar B, Lenarz T, Paasche G. Intraluminal three-dimensional optical coherence tomography - a tool for imaging of the Eustachian tube? *J Laryngol Otol.* 2019 Feb;133(2):87-94.
 24. Huisman JML, Verdam FJ, Stegeman I, de Ru JA. Treatment of Eustachian tube dysfunction with balloon dilation: a systematic review. *Laryngoscope.* 2018;128:237-247
 25. Browning GG, Gatehouse S. The prevalence of middle ear disease in the adult British population. *Clin Otolaryngol* 1992;17:317-21.
 26. Adil E, Poe D. What is the full range of medical and surgical treatments available for patients with Eustachian tube dysfunction? *Curr Opin Otolaryngol Head Neck Surg* 2014;22:8-15.
 27. McCoul ED, Mayer SI, Tabae A, Bedrosian JC, Marino MJ. Endoscopic Evaluation of the Eustachian Tube: assessment of a novel tool for grading Eustachian tube inflammation. *Int Forum Allergy Rhinol.* 2019 Mar;9(3):305-310.
 28. Kilic E, Gerek M, Karakoc O, Gamsizkan M. Effects of acidic and nonacidic reflux on the eustachian tube: An animal experiment. *Ear Nose Throat J.* 2018 Dec;97(12):E21-E27.
 29. McCoul ED, Anand VK, Christos PJ. Validating the clinical assessment of eustachian tube dysfunction: The Eustachian Tube Dysfunction Questionnaire (ETDQ-7). *Laryngoscope* 2012; 122:1137-41.
 30. Cao YR, Zhang J, Liu H, Zhang W. Clinical application of seven-item Eustachian Tube Dysfunction Questionnaire. *Lin Chung Er Bi Yan Hou Tou Jing Wai Ke Za Zhi.* 2018 Oct 5;32(19):1483-1486.
 31. Zeng H, Chen X, Xu Y, Zheng Y, Xiong H. Buteyko breathing technique for obstructive Eustachian tube dysfunction: Preliminary results from a randomized controlled trial. *Am J Otolaryngol.* 2019 May 17. pii: S0196-0709(19)30269-8.
 32. DiBartolomeo JR, Henry DF. A new medication to control patulous eustachian tube disorders. *Am J Otol.* 1992 July;13(4):323-327
 33. Chen DA, Luxford WM. Myringotomy and tube for relief of patulous eustachian tube symptoms. *Am J Otol.* 1990 July;11(4):272-273
 34. Ward BK, Ashry Y, Poe DS. Patulous Eustachian Tube Dysfunction: Patient Demographics and Comorbidities. *Otol Neurotol.* 2017 Oct;38(9):1362-1369.
 35. Yoshida H, Takahashi H, Morikawa M. Anatomy of the Surrounding Tissue of the Eustachian Tube in Patulous Eustachian Tube: 3 Tesla Magnetic Resonance Imaging Approach. *Otol Neurotol.* 2019 Feb;40(2):e107-e114.
 36. Van Roeyen S, Van de Heyning P, Van Rompaey V. Value and discriminative power of the seven-item eustachian tube dysfunction questionnaire: Value and Discriminative Power of the ETDQ-7. *Laryngoscope.* 2015 Nov;125(11):2553-6.
 37. Kim SJ, Shin SA, Lee HY, Park YH. Paper patching for patulous eustachian tube. *Acta Otolaryngol.* 2019 Feb;139(2):122-128.
 38. Alli A, Shukla R, Cook JL, Waddell A. A novel computed tomography guided, transcutaneous approach to treat refractory autophony in patients with a patulous Eustachian tube - a case series. *J Laryngol Otol.* 2019 Mar;133(3):201-204.
 39. Funamura JL, Said M, Lin SJ, McKinney S, Tollefson TT. Eustachian tube dysfunction in children with cleft palate: A tympanometric time-to-event analysis. *Laryngoscope.* 2019 Jun 13.
 40. D. Arunachalam, S. Pendem, P. Ravi, K.K. Raja V.B. Abnormalities of the muscles of the soft palate and their impact on auditory function in patients operated on for cleft palate: a case-control study. *Br J Oral Maxillofac Surg.* 2019 Jul;57(6):566-571.
 41. Paradise JL, Bluestone CD. Early treatment of the universal otitis media of infants with cleft palate. *Pediatrics* 1974;53:48-54.
 42. Lenarz T, Boenninghaus HG. Hals-Nasen-Ohrenheilkunde. 14. Auflage. Heidelberg: Springer; 2012. s. 1-488.
 43. Dave V, Ruparel M. Correlation of Eustachian Tube Dysfunction with Results of Tympanoplasty in Mucosal Type of Chronic Suppurative Otitis Media. *Indian J Otolaryngol Head Neck Surg.* 2019 Mar;71(1):10-13.
 44. V. Saravanan, R.V.Kumar, M.Vasudevan, Vineetha K. Study of Eustachian Tube Function in Normal Adults And Those With Middle Ear Disease. *IOSR Journal of Dental and Medical Sciences.* Volume 16, Issue 5 Ver. V (May. 2017), PP 76-8
 45. Ahmad M. Does balloon Eustachian tuboplasty increase the success rate in repair of subtotal tympanic membrane perforations with resistant tubal dysfunction. *Egypt J Ear Nose Throat Allied Sci.* 2013;14:97e101.
 46. Tarabichi M, Kapadia M. The role of transtympanic dilatation of the eustachian tube during chronic ear surgery. *Otolaryngol Clin North Am.* 2016;49:1149e1162.
 47. V. Shiny Sherlie, Ashish Varghese. ENT Changes of Pregnancy and Its Management. *Indian J Otolaryngol Head Neck Surg.* 2014 Jan; 66(Suppl 1): 6-9.
 48. Weissman A, Nir D, Shenhav R, Zimmer EZ, Joachims ZH, Danino J. Eustachian tube function during pregnancy. *Clin Otolaryngol Allied Sci.* 1993;18(3):212-214.
 49. Ockermann T, Reineke U, Upile T, Ebmeyer J, Sudhoff HH. Balloon dilatation eustachian tuboplasty: a clinical study. *Laryngoscope* 2010; 120:1411-6.
 50. Marc Dean, Melissa A.Pynnonen. In-Office Balloon Dilatation of the Eustachian Tube under Local Anesthesia. *Otolaryngol Clin N Am* 52 (2019) 509-520.
 51. McCoul ED, Anand VK. Eustachian tube balloon dilation surgery. *Int Forum Allergy Rhinol* 2012; 2: 191-8.
 52. Bast F, Frank A, Schrom T. Balloon dilatation of the Eustachian tube: postoperative validation of patient satisfaction. *ORL J Otorhinolaryngol Relat Spec* 2013; 75: 361-5.

53. Schroder S, Lehmann M, Ebmeyer J, Upile T, Sudhoff H. Balloon Eustachian Tuboplasty (BET): our experience of 622 cases. *Clin Otolaryngol.* 2015 Aralık; 40 (6): 629-38.
54. Li YQ, Chen YB, Yin GD, Zeng XL. Effect of balloon dilation eustachian tuboplasty combined with tympanic tube insertion in the treatment of chronic recurrent secretory otitis media. *Eur Arch Otorhinolaryngol.* 2019 Jun 13
55. Yu Si, Yu Bin Chen, Yu Guo Chu, Sui Jun Chen, Hao Xiong, Xi Ming Chen, Wu Hui He, Yi Qing Zheng, Zhi Gang Zhang. Effects of combination of balloon Eustachian tuboplasty with methylprednisolone irrigation on treatment of chronic otitis media with effusion in adults. *American Journal of Otolaryngology* Volume 39, Issue 6, November–December 2018, Pages 670-675.
56. Plaza G, Navarro JJ, Alfaro J, Sandoval M, Marco J. Consensus on treatment of obstructive Eustachian tube dysfunction with balloon Eustachiantuboplasty. *Acta Otorrinolaringol Esp.* 2019 May 24. pii: S0001-6519(19)30045-7.
57. Leichtle A, Hollfelder D, Wollenberg B, Bruchhage KL. Balloon Eustachian Tuboplasty in children. *Eur Arch Otorhinolaryngol.* 2017 Jun;274(6):2411-2419
58. F.Blanc, D.Ayache, M.N.Calmels, O.Deguine, M.François, N.Leboulanger, E.Lescanne, R.Marianowski, J.Nevoux, R.Nicollas, S.Tringali, N.Tessier, V.Franco-Vidal, P.Bordure, M.Mondain. Management of otitis media with effusion in children. *Société française d'ORL et de chirurgie cervico-faciale clinical practice guidelines.* *European Annals of Otorhinolaryngology, Head and Neck Diseases.* Volume 135, Issue 4, August 2018, Pages 269-273.
59. Pauline Vanneste, Cyril Page. Otitis media with effusion in children: Pathophysiology, diagnosis, and treatment. *A review.* *J Otol.* 2019 Jun; 14(2): 33–39.
60. Casselbrant ML, Mandel EM, Rosenfeld RM, Bluestone CD. *Kanıtı Dayalı Otitis Media. ikinci basım.* BC Decker Inc; Hamilton: 2003. *Epidemiyoloji; sayfa 147-162.*
61. Emami A, Pirbonyeh N, Moattari A, Bazargani A, Motamedifar M. Risk of otitis media with effusion (OME) in children by *Pseudomonas aeruginosa*. *Int J Pediatr Otorhinolaryngol.* 2019 Jun 19;125:6-10
62. A. Qureishi, Y. Lee, K. Belfield, J.P. Birchall, M. Danie-
Update on otitis media: prevention and treatment *Infect Drug Resist,* 7 (2014), pp. 15-24
63. L. Monasta, L. Ronfani, F. Marchetti, M. Montico, L. Vecchi Brumatti, A. Bavcar, *et al.* **Burden of disease caused by otitis media: systematic review and global estimates** *PLoS ONE,* 7 (2012), p. e36226.
64. Kucur C, Şimşek E, Kuduban O, Özbay İ. Prevalence of and risk factors for otitis media with effusion in primary school children: case control study in Erzurum, Turkey. *Turk J Pediatr.* 2015 May-Jun;57(3):230-5.
65. Pauline Vanneste, Cyril Page. Otitis media with effusion in children: Pathophysiology, diagnosis, and treatment. *A review.* *Journal of Otology* Volume 14, Issue 2, June 2019, Pages 33-39
66. Reema Padia, Jeremiah A. Alt, Karen Curtin, Harlan R. Muntz, Richard R. Orlandi, Justin Berger, Jeremy D. Meier. Environmental contributions to otitis media requiring tympanostomy tubes. *International Journal of Pediatric Otorhinolaryngology.* Volume 101, October 2017, Pages 97-101
67. Mills R, Hathorn I. Aetiology and pathology of otitis media with effusion in adult life. *J Laryngol Otol.* 2016 May;130(5):418-24.
68. A.Yakoot, S.Giusiano, M.Sanjuan, A.Mardassi, J.Magnan, A.Devèze. An unusual cause of serous otitis media. *European Annals of Otorhinolaryngology, Head and Neck Diseases.* Volume 127, Issue 4, September 2010, Pages 156-158
69. Charusripan P, Khattiyawittayakun L. The effectiveness of myringotomy and ventilation tube insertion versus observation in post-radiation otitis media with effusion. *Eur Arch Otorhinolaryngol.* 2017 Sep;274(9):3283-3290.
70. Christensen JG, Wessel I, Gothelf AB, Homøe P. Otitis media with effusion after radiotherapy of the head and neck: a systematic review. *Acta Oncol.* 2018 Aug;57(8):1011-1016.
71. Durgut O, Dikici O. The effect of adenoid hypertrophy on hearing thresholds in children with otitis media with effusion. *Int J Pediatr Otorhinolaryngol.* 2019 Jun 1;124:116-119.
72. L.Skoloudik, D.Kalfert, T.Valenta, V.Chrobok. Relation between adenoid size and otitis media with effusion. *European Annals of Otorhinolaryngology, Head and Neck Diseases.* Volume 135, Issue 6, December 2018, Pages 399-402.
73. F.R. Amaee, S.D. Comis, M.P. Osborne, S. Drew, M.J. Tarlow. Possible involvement of nitric oxide in the sensorineural hearing loss of bacterial meningitis. *Acta Otolaryngol,* 117 (1997), pp. 329-336.
74. C.K. Rhee. Candidate's thesis: platelet-activating factor-induced hearing loss: mediated by nitric oxide? *Laryngoscope,* 113 (2003), pp. 2059-2066.
75. M.Ates, C.Cevik, R.Dokuyucu, O.Berber, S.Colak, M.Izmirli. The endothelial nitric oxide synthase (eNOS) polymorphism in otitis media with effusion (OME). *European Annals of Otorhinolaryngology, Head and Neck Diseases.* Volume 134, Issue 1, February 2017, Pages 3-5 February 2017, Pages 3-5.
76. Dae Woong Kang, Sung Hwa Dong, Sang Hoon Kim, Young Il Kim, Dong Choon Park, Seung Geun Yeo. Expression of endoplasmic reticulum stress-related mRNA in otitis media with effusion. *International Journal of Pediatric Otorhinolaryngology* Volume 121, June 2019, Pages 109-113.
77. Ji-Jin Yao, Guan-Qun Zhou, Li Lin, Wang-Jian Zhang, Ying-Lin Peng, Lei Chen, Ling-Long Tang, Yan-Ping Mao, Jun Ma & Ying Sun. Dose-volume factors associated with ear disorders following intensity modulated radiotherapy in nasopharyngeal carcinoma. *Scientific Reports* September 2015(5): Article number: 13525.
78. Van Hoecke, H., De Paepe, A.-S., Lambert, E., Van Belleghem, J.D., Cools, P., Van Simaey, L., Deschaght, P., Vaneechoutte, M., Dhooze, I. *Haemophilus influenzae* biofilm formation in chronic otitis media with effusion. *European Archives of Oto-Rhino-Laryngology* Volume 273, Issue 11, 1 November 2016, Pages 3553-3560.
79. Katherine Belfield, Roger Bayston, J.P. Birchall, Matija Daniel. Do orally administered antibiotics reach concentrations in the middle ear sufficient to eradicate

- planktonic and biofilm bacteria? A review. *International Journal of Pediatric Otorhinolaryngology* Volume 79, Issue 3, March 2015, Pages 296-300.
80. J.S. Gravel, I.F. Wallace Effects of otitis media with effusion on hearing in the first 3 years of life. *J Speech Lang Hear Res*, 43 (2000), pp. 631-644.
81. F.Simon, M.Haggard, R.M.Rosenfeld, H.Jia, S.Peer, M.-N.Calmels, V.Couloigner, N.Teissier. International consensus (ICON) on management of otitis media with effusion in children. *European Annals of Otorhinolaryngology, Head and Neck Diseases* Volume 135, Issue 1, Supplement, February 2018, Pages S33-S39.
82. R.M. Rosenfeld, J.J. Shin, S.R. Schwartz, R. Coggins, L. Gagnon, J.M. Hackell, et al. Clinical practice guideline: otitis media with effusion (update). *Otolaryngol Head Neck Surg*, 154 (2016), pp. S1-S41.
83. Z. Önal, F. Çullu Çokuğraş, H. Işıldak, et al. Evaluation of the likelihood of reflux developing in patients with recurrent upper respiratory infections, recurrent sinusitis or recurrent otitis seen in ear-nose-throat outpatient clinics. *Turk J Pediatr*, 57 (2015), pp. 258-265.
84. I. Williamson, J. Vennik, A. Harnden, et al. An open randomised study of autoinflation in 4- to 11-year-old school children with otitis media with effusion in primary care. *Health Technol Assess*, 19 (2015), pp. 1-150.
85. L. Califano, F. Salafia, S. Mazzone, G. D'Ambrosio, Malafante, A. Vassallo A comparative randomized study on the efficacy of a systemic steroid therapy vs. a thermal therapy in otitis media with effusion in children. *Minerva Pediatr*, 68 (2014), pp. 241-249.
86. P. Mirandola, G. Gobbi, C. Malinverno, et al. Impact of sulphurous water politzer inhalation on audiometric parameters in children with otitis media with effusion. *Clin Exp Otorhinolaryngol*, 6 (2013), pp. 7-11.
87. R. Bhargava, A. Chakravarti A double-blind randomized placebo-controlled trial of topical intranasal mometasone furoate nasal spray in children of adenoidal hypertrophy with otitis media with effusion *Am J Otolaryngol*, 35 (2014), pp. 766-770.
88. Francis NA, Waldron CA, Cannings-John R, Thomas-Jones E, Winfield T, Shepherd V, Harris D, Hood K, Fitzsimmons D, Roberts A, Powell CV, Gal M, Jones S, Butler CC. Oral steroids for hearing loss associated with otitis media with effusion in children aged 2-8 years: the OSTRICH RCT. *Health Technol Assess*. 2018 Nov;22(61):1-114.
89. R.M. Rosenfeld, S.R. Schwartz, M.A. Pynnonen, D.E. Tunkel, H.M. Hussey, J.S. Fichera, et al. Clinical practice guideline: tympanostomy tubes in children. *Otolaryngol Head Neck Surg*, 149 (2013), pp. S1-S35
90. Ahmet Kutluhan , Behçet Tarlak , Hüseyin Çetin , Elif Ersoy Kallioğlu , Kazım Bozdemir , Mustafa Kemal Demir. Mastoid antral ventilation tube; new treatment modality for recurrent otitis media with effusion and its long term results. *Int J Clin Exp Med*. 2015; 8(4): 5774-5780.
91. Joseph E.Dohar, Chung H.Lu. Tube patency: Is there a difference following otic drop administration? *American Journal of Otolaryngology*. Volume 39, Issue 4, July-August 2018, Pages 392-395.
92. B.D. Djurhuus, K. Christensen The impact of ventilation tube in otitis media on the risk of cholesteatoma on a national level. *Int J Pediatr Obes*, 79 (2015), pp. 605-609.
93. Serdar Kaya, Vladimir Tsuprun, Ömer Hızlı, Patricia A. Schachern BS, Michael M. Paparella, Sebahattin Cureoglu. Cochlear changes in serous labyrinthitis associated with silent otitis media: A human temporal bone study. *American Journal of Otolaryngology* Volume 37, Issue 2, March-April 2016, Pages 83-88.
94. Bayramoğlu I, Ardiç FN, Kara CO, Ozüer MZ, Katircioğlu O, Topuz B. Importance of mastoid pneumatization on secretory otitis media. *Int J Pediatr Otorhinolaryngol*. 1997 May 4;40(1):61-6.
95. P.V. Vlastarakos, T.P. Nikolopoulos, S. Korres, E. Tavoulari, A. Tzagaroulakis, E. Ferekidis. Grommets in otitis media with effusion: the most frequent operation in children. But is it associated with significant complications. *Eur J Pediatr*, 166 (2007), pp. 385-391.
96. Hüseyin Yaman, Süleyman Yılmaz, Ender Güçlü, Buğra Şubesi, Nihal Alkan, Özcan Öztürk. Otitis media with effusion: Recurrence after tympanostomy tube extrusion. *International Journal of Pediatric Otorhinolaryngology* Volume 74, Issue 3, March 2010, Pages 271-274.
97. Nathalie Klopp-Dutote, Catherine Kolski, Vladimir Strunski, Cyril Page. Tympanostomy tubes for serous otitis media and risk of recurrences. *International Journal of Pediatric Otorhinolaryngology*. Volume 106, March 2018, Pages 105-109.