

10. BÖLÜM

PELVİS KOMPRESYON SENDROMLARI

Dr. Öğr. Üyesi Fatih ADA¹
Uzm. Dr. Cemil AY²

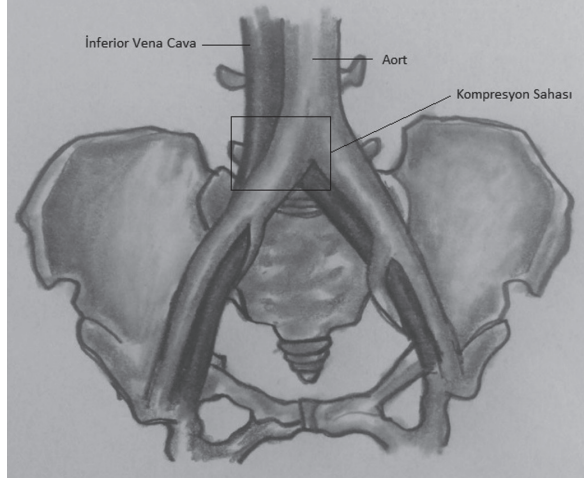
› İliyak Ven Kompresyon Sendromu (May-Thurner Sendromu, Cockett Sendromu)

Giriş: İliyak ven kompresyon sendromu; iliyak venin, arteriyal sistem ile vertebralar arasında sıkışması olarak tanımlanır. Bu kompresyon sağ iliyak vende de olabileceği gibi sol taraflı olarak çok daha sık görülür. Sol ana iliyak venin, sağ iliyak arter ile 5. Lumbal vertebra arasında görülen kompresyonu en sık görülen formudur (1). Bu kompresyon sadece tek bir noktada olabileceği gibi hem sağ ana iliyak arterin hem de sol internal iliyak arterin iki farklı bölgeden sol ana iliyak veni komprese ettiği vakalarda bildirilmiştir (2). Eksternal kompresyona bağlı olarak lokal obstrüksiyon ve spur gelişimini takiben venöz outflowda azalma ve venöz hipertansiyon gelişir. Venöz hipertansiyon sonrası etkilenen ekstremitede ödem, varis ve ağrı kaçınılmaz olmaktadır. Ayrıca gelişen venöz kollaterallerin bölgesine bağlı olarak pelvik ağrı, karın ağrısı, yan ağrısı gibi semptomlarda görülebilmektedir. Hastalığın temelinde arteriyal bası yer almakla birlikte batının ve pelvisin kitleleri, iliyak arterin pür anevrizmaları veya omurga cerrahisinde kullanılan enstrümanlar da iliyak ven kompresyon sendromuna benzer tablolara yol açabilir (3-5).

1851 yılında Virchow sol bacak derin venöz tromboz insidansının sağ bacağına göre artmış olmasının sebebi olarak sağ ana iliyak arterin sol ana iliyak veni çaprazlamasından dolayı olduğunu öne sürdü. Bundan yaklaşık 50 yıl sonra McMurrich postmortem incelemelerinde sol ana iliyak ven obstrüksiyonunu %29,9 olarak buldu. Sol iliyak ven kompresyonunun neden olduğu izole sol alt ekstremitate

¹ Sivas Cumhuriyet Üniversitesi Tıp Fakültesi, Kalp ve Damar Cerrahisi ABD, Sivas

² Tunceli Devlet Hastanesi, Üroloji Kliniği, Tunceli



Şekil 2: İliokaval bileşke kompresyonu.

Kaynaklar

1. Brazeau NF, Harvey HB, Pinto EG, Deipolyi A, Hesketh RL, Oklu R. May-Thurner syndrome: diagnosis and management. *Vasa* 2013; 42 (2): 96 – 105.
2. Steinberg JB, Jacocks MA. May-Thurner syndrome: a previously unreported variant. *Ann Vasc Surg* 1993; 7: 577 - 81.
3. Woo EJ, Ogilvie RA, Krueger VS, Lundin M, Williams DM. Iliac vein compression syndrome from anterior perforation of a pedicle screw. *J Surg Case Rep* 2016. 2016 pii: Rjw003. doi: 101093/jscr/rjw003.
4. Ada F, Yazıcioğlu L, Dikmen Yaman N, Gümüş F, Çakıcı M, Özçınar E, et al. A. Giant chondrosarcoma acting as lower limb deep venous thrombosis. *Turk Gogus Kalp Dama Suppl* 2014;1(P-664):398.
5. Mullens W, De Keyser J, Van Dorpe A, Meuris B, Flameng W, Herregods MC, et al. Migration of two venous stents into the right ventricle in a patient with May-Thurner syndrome. *Int J Cardiol.* 2006;110:114-5.
6. Cockett FB, Thomas ML, Negus D. Iliac vein compression. --Its relation to iliofemoral thrombosis and the postthrombotic syndrome. *Br Med J* 1967;2:14-9.
7. Narayan A, Eng J, Carmi L, McGrane S, Ahmed M, Sharrett AR, et al. Iliac vein compression as risk factor for left- versus right-sided deep venous thrombosis: case-control study. *Radiology* 2012; 265 (03) 949-57.
8. Wu M, Luo X, Zhang F. Incidence and risk factors of deep venous thrombosis in asymptomatic iliac vein compression: a prospective cohort study. *Chin Med J.* 2016;129:2149-52.
9. Burke RM, Rayan SS, Kasirajan K, Chaikof EL, Milner R. Unusual case of right-sided May-Thurner syndrome and review of its management. *Vascular* 2006;14:47-50.
10. Abboud G, Midulla M, Lions C, El Ngheoui Z, Gengler L, Martinelli T, et al. "Right-sided" May-Thurner syndrome. *Cardiovasc Intervent Radiol* 2010;33:1056-9.
11. Molloy S, Jacob S, Buckenham T, Khaw KT, Taylor RS. Arterial compression of the right common iliac vein; an unusual anatomical variant. *Cardiovascular Surgery* 2002;10: 291 -2.

12. Kim YH, Ko SM, Kim HT. Spontaneous rupture of the left common iliac vein associated with May Thurner syndrome: successful management with surgery and placement of an endovascular stent. *Br J Radiol* 2007;80:176-9.
13. Dheer S, Joseph AE, Drooz A. Retroperitoneal hematoma caused by a ruptured pelvic varix in a patient with iliac vein compression syndrome. *J Vasc Interv Radiol* 2003; 14: 387-90.
14. Bomalaski A, Mills J, Argueso L. Iliac vein compression syndrome: An unusual cause of varicocele. *J Vasc Surg* 1993; 18:1065.
15. Kiernan TJ, Yan BP, Cubeddu RJ, Moreno PR, Gupta V, Inglesis I, et al. May-Thurner syndrome in patients with cryptogenic stroke and patent foramen ovale: an important clinical association. *Stroke* 2009;40:1502-4.
16. Greer DM, Buonanno FS. Cerebral infarction in conjunction with patent foramen ovale and May-Thurner syndrome. *J Neuroimaging* 2001;11:432-4.
17. Cockett FB, Thomas ML, Negus D. Iliac vein compression: its relation to iliofemoral thrombosis and the post-thrombotic syndrome. *BMJ* 1967; 2:14-6.
18. Ou-Yang L, Lu GM. Underlying Anatomy and Typing Diagnosis of May Thurner Syndrome and Clinical Significance: An Observation Based on CT. *Spine*, 2016;41(21), E1284-E91.
19. Shebel ND, Whalen CC. Diagnosis and management of iliac vein compression syndrome. *J Vasc Nurs* 2005; 23: 10 – 17; 18 – 9.
20. May R, Thurner J. The cause of the predominately sinistral occurrence of thrombosis of the pelvic veins. *Angiology* 1957;8:419-27.
21. Ehrlich WE, Krumbhaar EB. A frequent obstructive anomaly of the mouth of the left common iliac vein. *Am Heart J* 1943;26:737-50.
22. Taheri SA, Nowakowski P, Pendergast D, Cullen J, Pisano S, Boman L. Iliocaval compression syndrome. *Phlebology* 1987; 2: 173-9.
23. Kibbe MR, Ujiki M, Goodwin AL, Eskandari M, Yao J, Matsumura J. Iliac vein compression in an asymptomatic patient population. *J Vasc Surg* 2004;39:937-43.
24. Moreland NC, Ujiki M, Matsumura JS, Morasch MD, Eskandari MK, Pearce WH, et al. Decreased incidence of left common iliac vein compression in patients with abdominal aortic aneurysms. *J Vasc Surg* 2006; 44:595– 600.
25. Nazzal M, El-Fedaly M, Kazan V, Qu W, Renno AW, Al-Natour M, et al. Incidence and clinical significance of iliac vein compression. *Vascular*. 2015;23:337-43.
26. Ada F, Emren SV, Çelik E, Kılıç AT. May-Thurner Syndrome In A Young Female Patient. *Turk Gogus Kalp Dama Suppl* 2016;1(EP-300):180.
27. Raffini L, Raybagkar D, Cahill AM, Kaye R, Blumenstein M, Manno C. May Thurner syndrome (iliac vein compression) and thrombosis in adolescents. *Pediatr Blood Cancer*. 2006;47:834-8.
28. Oguzkurt L, Ozkan U, Ulsan S, Koc Z, Tercan F. Compression of the left common iliac vein in asymptomatic subjects and patients with left iliofemoral deep vein thrombosis. *J Vasc Interv Radiol* 2008;19:366-70.
29. Traves KP, Studdiford JS, Pickle S, Tully AS. Edema: Diagnosis and management. *Am Fam Physician* 2013;88:102-10.
30. Ada F, Emren V. A New-Proposal Physical Examination Test for Unilateral Lower Extremity Edema. *The Heart Surg Forum* 2018; 21(5): e392-e400.
31. Wolpert LM, Rahmani O, Stein B, Gallagher JJ, Drezner AD. Magnetic resonance venography in the diagnosis and management of May-Thurner syndrome. *Vasc Endovascular Surg* 2002;36:51-7.

32. Oğuzkurt L, Ozkan U, Tercan F, Koç Z. Ultrasonographic diagnosis of iliac vein compression (May-Thurner) syndrome. *Diagn Interv Radiol* 2007; 13:152-5.
33. Neglen P, Raju S. Intravascular ultrasound scan evaluation of the obstructed vein. *J Vasc Surg* 2002;35:694-700.
34. Forauer AR, Gemmete JJ, Dasika NL, Cho KJ, Williams DM. Intravascular ultrasound in the diagnosis and treatment of iliac vein compression (May-Thurner) syndrome *J Vasc Interv Radiol* 2002;13: 523-7.
35. Raju S, Neglen P. High prevalence of nonthrombotic iliac vein lesions in chronic venous disease: a permissive role in pathogenicity. *J Vasc Surg* 2006;44:136-43.
36. Ahmed HK, Hagspiel KD. Intravascular ultrasonographic findings in May-Thurner syndrome (iliac vein compression syndrome). *J Ultrasound Med* 2001; 20:251-6.
37. Lugo-Fagundo C, Nance JW, Johnson PT, Fishman EK. May-Thurner syndrome: MDCT findings and clinical correlates. *Abdom Radiol (NY)* 2016;41:2026-30.
38. Laissy JP, Cinqualbre A, Loshkajian A, Henry-Feugeas MC, Crestani B, Riquelme C, et al. Realtime assessment of deep venous thrombosis in the lower limbs and pelvis: MR venography versus duplex Doppler sonography. *AJR Am J Roentgenol.* 1996;167:971-5.
39. Fraser DG, Moody AR, Morgan PS, Martel A. Iliac compression syndrome and recanalization of femoropopliteal and iliac venous thrombosis: a prospective study with magnetic resonance venography. *J Vasc Surg* 2004;40:612-9.
40. Jeon UB, Chung JW, Jae HJ, Kim HC, Kim SJ, Ha J, et al. May-Thurner Syndrome Complicated by Acute Iliofemoral Vein Thrombosis: Helical CT Venography for Evaluation of Long-Term Stent Patency and Changes in the Iliac Vein. *AJR Am J Roentgenol.* 2010;195: 751 – 7.
41. Oğuzkurt L, Tercan F, Pourbagher MA, Kizilkilic O, Turkoz R, Boyvat F. Computed tomography findings in 10 cases of iliac vein compression (May-Thurner) syndrome. *Eur J Radiol* 2005;55:421-5.
42. Berger A, Jaffe JW, York TN. Iliac compression syndrome treated with stent placement. *J Vasc Surg* 1995; 21: 510-4.
43. Knuttinen MG, Naidu S, Oklu R, Kriegshauser S, Eversman W, Rotellini L, et al. May-Thurner: diagnosis and endovascular management. *Cardiovasc Diagn Ther* 2017;7(Suppl 3):S159-S64.
44. Cil BE, Akpınar E, Karcaaltincaba M, Akinci D. Case 76: May-Thurner syndrome. *Radiology* 2004;233:361-5.
45. Neglén P, Thrasher TL, Raju S. Venous outflow obstruction: an underestimated contributor to chronic venous disease. *J Vasc Surg* 2003;38: 879-85.
46. Neglén P, Hollis KC, Olivier J, Raju S. Stenting of the venous outflow in chronic venous disease: long-term stent related outcome, clinical, and hemodynamic result. *J Vasc Surg* 2007;46:979-90.
47. Liu Z, Gao N, Shen L, Yang J, Zhu Y, Li Z, Si Y. Endovascular treatment for symptomatic iliac vein compression syndrome: a prospective consecutive series of 48 patients. *Ann Vasc Surg.* 2014;28:695-704.
48. Mussa FF, Peden EK, Zhou W, Lin PH, Lumsden AB, Bush RL. Iliac vein stenting for chronic venous insufficiency. *Texas Heart Institute Journal* 2007; 34: 60 – 6.
49. Neglen P, Raju S. Balloon dilation and stenting of chronic iliac vein obstruction: technical aspects and early clinical outcome. *J Endovasc Ther,* 2000;7: 79-91.
50. Oğuzkurt L, Tercan F, Sener M. Successful endovascular treatment of iliac vein compression (May-Thurner) syndrome in a pediatric patient. *Cardiovasc Intervent Radiol,* 2006;29: 446-9.

51. Budnur SC, Singh B, Mahadevappa NC, Reddy B, Nanjappa MC. Endovascular treatment of iliac vein compression syndrome(May-Thurner). *Cardiovasc Interv Ther*, 2013;28:101-5.
52. O'Sullivan GJ, Semba CP, Bittner CA, Kee ST, Razavi MK, Sze DY, et al. Endovascular management of iliac vein compression (may-thurner) syndrome. *J Vasc Interv Radiol* 2000;11:823-36.
53. Kim JY, Choi D, Ko YG, Park S, Jang Y, Lee DY. Percutaneous treatment of deep vein thrombosis in May-Thurner syndrome. *Cardiovasc Intervent Radiol*, 2006;29:571-5.
54. Xue GH, Huang XZ, Ye M, Liang W, Zhang H, Zhang JW, et al. Catheter-directed thrombolysis and stenting in the treatment of iliac vein compression syndrome with acute iliofemoral deep vein thrombosis: outcome and follow-up. *Ann Vasc Surg*. 2014;28(4):957-63.
55. Bozkaya H, Cinar C, Ertugay S, Korkmaz M, Guneyli S, Posacioglu H, et al. Endovascular Treatment of Iliac Vein Compression (May-Thurner) Syndrome: Angioplasty and Stenting with or without Manual Aspiration Thrombectomy and Catheter-Directed Thrombolysis. *Ann Vasc Dis* 2015;8(1):21-8.
56. Lou WS, Gu JP, He X, Chen L, Su H-B, Chen G-P, et al.. Endovascular treatment for iliac vein compression syndrome: a comparison between the presence and absence of secondary thrombosis. *Korean J Radiol* 2009;10:135-43.
57. Zhu QH, Zhou CY, Chen Y, Wang J, Mo HY, Luo MH, et al. Percutaneous manual aspiration thrombectomy followed by stenting for iliac vein compression syndrome with secondary acute isolated iliofemoral deep vein thrombosis: a prospective study of single-session endovascular protocol. *Eur J Vasc Endovasc Surg*. 2014;47:68-74.
58. Mickley V, Schwagierek R, Rilinger N, Gorich J, Sunder-Plassmann L. Left iliac venous thrombosis caused by venous spur: treatment with thrombectomy and stent implantation. *J Vasc Surg* 1998;28:492-7.
59. Patel NH, Stookey KR, Ketcham DB, Cragg AH. Endovascular management of acute extensive iliofemoral deep venous thrombosis caused by May-Thurner syndrome. *J Vasc Interv Radiol*, 2000;11: 1297-1302.
60. Binkert CA, Schoch E, Stuckmann G, Largiader J, Wigger P, Schoepke W, et al. Treatment of pelvic venous spur (May-Thurner syndrome) with self-expanding metallic endoprostheses. *Cardiovasc Intervent Radiol*, 1998;21: 22-6.
61. Kwak H, Han Y, Lee Y, Jin G, Chung G. Stents in common iliac vein obstruction with acute ipsilateral deep thrombosis: early and late results. *J Vasc Interv Radiol*. 2005; 16: 815-22.
62. Lamont JP, Pearl GJ, Patetsios P, Warner MT, Gable DR, Garrett W, et al. Prospective evaluation of endoluminal venous stents in the treatment of the May-Thurner syndrome. *Ann Vasc Surg*, 2002;16: 61-4.
63. Oguzkurt L, Tercan F, Ozkan U, Gulcan O. Iliac vein compression syndrome: Outcome of endovascular treatment with long-term follow-up. *Eur J Radiol*. 2008; 68: 487-92.
64. Vedantham S, Millward SF, Cardella JF, Hofmann LV, Razavi MK, Grassi CJ, et al. Society of Interventional Radiology position statement: treatment of acute iliofemoral deep vein thrombosis with use of adjunctive catheter-directed intrathrombus thrombolysis. *J Vasc Interv Radiol* 2006;17:613-6.
65. Meissner MH, Gloviczki P, Comerota AJ, Dalsing MC, Eklof BG, Gillespie DL, et al. Early thrombus removal strategies for acute deep venous thrombosis: clinical practice

- guidelines of the Society for Vascular Surgery and the American Venous Forum. *J Vasc Surg* 2012;55:1449-62.
66. Mahnken AH, Thomson K, de Haan M, O'Sullivan GJ. CIRSE Standards of Practice Guidelines on Iliocaval Stenting. *Cardiovasc Intervent Radiol* 2014; 37:889-97.
 67. Raju S. Best management options for chronic iliac vein stenosis and occlusion. *J Vasc Surg* 2013;57:1163-9.
 68. Knipp BS, Ferguson E, Williams DM, Dasika NJ, Cwikiel W, Henke PK, et al. Factors associated with outcome after interventional treatment of symptomatic iliac vein compression syndrome. *Journal of Vascular Surgery* 2007; 46:743-9.
 69. Mullens W, De Keyser J, Van Dorpe A, Meuris B, Flameng W, Herregods MC, et al. Migration of two venous stents into the right ventricle in a patient with May-Thurner syndrome. *Int J Cardiol*. 2006;110:114-5.
 70. Akers DL, Creado B, Hewitt RL. Iliac vein compression syndrome: case report and review of the literature. *J Vasc Surg* 1996;24:477-81.
 71. Petersen MJ, Brewster DC. Iliac Vein Compression Syndrome. *Perspectives in Vascular Surgery and Endovascular Therapy* 1995;8(1):91-6.
 72. Cockett FB, Thomas ML. The iliac compression syndrome. *Br J Surg* 1965;52:816-21.
 73. Rigas A, Vomvourimis A, Tsardakas E. Iliac compression syndrome: Report of ten cases. *J Cardiovasc Surg* 1970;11: 389-92.
 74. Jaszczak P, Mathiesen FR. The iliac compression syndrome. *Acta Chit Scand* 1978;144:133-6.
 75. Taheri SA, Williams J, Powell S, et al. Ileocaval compression syndrome. *Am J Surg* 1987;154:169-72.
 76. Taheri SA, Taheri PA, Schultz RO, et al. Ileocaval compression syndrome. *Contemp Surg* 1992;40:9-14.
 77. Trimble C, Bemstein EF, Pomerantz M, et al. A prosthetic bridging device to relieve iliac venous compression. *Surg Forum* 1972;23:249-51.
 78. Ellis PR, Del Rosario VC. Left iliac vein "adhesions." *Surgery* 1968;63:166-72.
 79. Ferris E J, IArn WN, Smith PL, et al. May-Thurner syndrome. *Radiology* 1983;147:29-31.
 80. Cockett FB. Venous causes of swollen leg. *Br J Surg* 1967;54:891-4.
 81. Fretz V, Binkert CA. Compression of the inferior vena cava by the right iliac artery: a rare variant of May-Thurner syndrome. *Cardiovasc Intervent Radiol* 2010;33: 1060-3.
 82. Sonin AH, Mazer MJ, Powers TA. Obstruction of the inferior vena cava: A multiple-modality demonstration of causes, manifestations, and collateral pathways. *Radiographics* 1992;12:309-22.
 83. Hurst DR, Forauer AR, Bloom JR, Greenfield LJ, Wakefield TW, Williams DM. Diagnosis and endovascular treatment of iliac vein compression syndrome. *J Vasc Surg* 2001;34:106-13.
 84. Hage AN, Srinivasa RN, Abramowitz SD, Cooper KJ, Khaja MS, Barnes GD, et al. Endovascular iliac vein reconstruction for the treatment of iliac vein thrombosis: From imaging to intervention. *Vascular Medicine*, 2018;23(3):267-75.