

Bölüm 15

FEMUR BAŞI AVASKULER NEKROZU

Erol KAYA¹
Levent HOROZ²

GİRİŞ

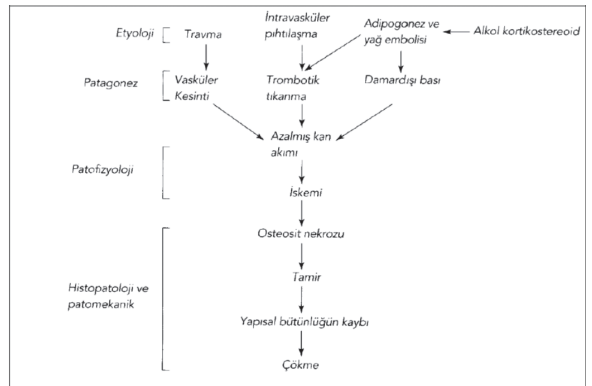
Osteonekroz, iskemi sonucu kemik doku ölümü anlamına gelmektedir. Femur başı osteonekrozu femur başında osteositlerin ölümü ve bunu takip eden dönemde kemik iliği değişiklikleri, değişen ölçüde iyileşme paternlerini izleyen femur başı kollapsı ve sekonder kalça eklemi osteoartritine yol açan yapısal değişiklikleri ifade eder(1). Avasküler nekroz gelişimi travmatik yada atravmatik avasküler nekrozun nedeni multifaktöryel olup genetik ve risk faktörlerine maruz kalmak sayılabilir (2). Amerikada her yıl 20.000 yeni tanı vaka tanımlanmıştır (3). Dünya çapında gerçek insidansı bilinmemektedir. Total kalça artroplastisi uygulanan vakaların %5-10 unda sebepfemur başı avasküler nekrozudur (4). Femur başı avasküler nekrozu (FBAN) 30- 50 yaş arası erkeklerde daha sık görülmektedir (5).%30-50 bilateral olup, sistemik hastalıklarda çoklu eklem tutulumu görülebilir (6). Erken tanı alan ve tedavisiz bırakılan FBAN vakalarının %80'inde femur başı kollapsı görülmektedir (7).

ETYOPATOGENEZ

Femur başı avasküler nekrozu (FBAN), progresif multifaktöryel bir rahatsız olup genellikle orta yaş erişkinleri özellikle 25-50 yaş arası grubu etkilemektedir. FBAN klinik olarak femur başındaki subkondral kemiğin kanlanmasında azalma ile neti-

celenen multifaktöryel bir etiyolojiye sahiptir. Bu durum osteosit ölümüne ve kalçanın dejeneratif artritine gidecek eklem yüzeyinde progresif kollapsa neden olur(8). FBAN gelişiminde tek başına bir etken neden olmamakla birlikte osteosit ölümü, yağ hücre hipertrofisi, yağ embolisi, intravasküler koagülasyon ve vasküler yetmezlik gibi çeşitli nedenler suçlanmıştır(9). (Tablo1.)

Tablo 1. Osteonekroz Patogenezi



Alkol kullanımı, glukokortikoid kullanımı, hematolojik rahatsızlıklar (orak hücreli anemi, talasemi, polisitemi, miyeloproliferatif hastalıklar), KBY, Cushing sendromu, hiperkolestrolemi, gebelik vb. etkenler FBAN'un bilinen en sık nedenleridir. Femur boyun kırığı ve kalça çıkığı gibi nedenler de etiyolojide yer almaktadır (10). Aynı zamanda genetik bir takım etkenlerinde FBAN gelişiminde rol oynadığı ileri sürülmektedir. En

¹ Op. Dr. Erol KAYA, Merzifon Kara Mustafa Paşa Devlet Hastanesi, erol_kaya@live.com

² Op.Dr. Levent HOROZ, Suluova Devlet Hastanesi, dr.leventhoroz@gmail.com

KAYNAKÇA

- Lau RL, Perruccio AV, Evans H. et al. (2014). Stem cell therapy for the treatment of early stage avascular necrosis of the femoral head: a systematic review. *BMC musculoskeletal disorders*, 15(1), 156.
- Parsons SJ, Steele N. (2007). Osteonecrosis of the femoral head: Part 1—Aetiology, pathogenesis, investigation, classification. *Current orthopaedics*, 21(6), 457-463.
- Lieberman JR, Berry DJ, Mont MA, et al (2003). Osteonecrosis of the hip: management in the 21st century. *Instructional course lectures*, 52, 337-355
- Malizos KN, Karantanas AH, Varitimidis SE, et al (2007). Osteonecrosis of the femoral head: etiology, imaging and treatment. *European journal of radiology*, 63(1), 16-28.
- Lieberman JR, Berry DJ, Mont MA, et al. (2002). Osteonecrosis of the hip: management in the twenty-first century. *JBJS*, 84(5), 834-853.
- Urbaniak JR (2004). Avascular necrosis of the femoral head: etiology, pathophysiology, classification, and current treatment guidelines. *American journal of orthopaedics (Belle Mead, NJ)*, 33(7), 327-332..
- Min BW, Song KS, Cho CH, et al (2008). Untreated asymptomatic hips in patients with osteonecrosis of the femoral head. *Clinical orthopaedics and related research*, 466(5), 1087-1092.
- Kamal D, Traistaru R, Alexandru DO, et al (2013). Epidemiologic Study of Avascular Necrosis of the Femoral Head. *Current health sciences journal*, 39(3).
- Liu LH, Zhang QY, Sun W, et al (2017). Corticosteroid-induced osteonecrosis of the femoral head: detection, diagnosis, and treatment in earlier stages. *Chinese medical journal*, 130(21), 2601.
- Aoyama T, Goto K, Kakinoki R, et al (2014). An exploratory clinical trial for idiopathic osteonecrosis of femoral head by cultured autologous multipotent mesenchymal stromal cells augmented with vascularized bone grafts. *Tissue Engineering Part B: Reviews*, 20(4), 233-242.
- Kutlar A, Kutlar F, Turker I, et al. (2001). The methylene tetrahydrofolate reductase (C677T) mutation as a potential risk factor for avascular necrosis in sickle cell disease. *Hemoglobin*, 25(2), 213-217.
- Hong JM, Kim TH, Kim HJ, et al (2010). Genetic association of angiogenesis-and hypoxia-related gene polymorphisms with osteonecrosis of the femoral head. *Experimental & molecular medicine*, 42(5), 376-385.
- Glueck CJ, Freiberg RA, Oghene J, et al. (2007). Association between the T-786C eNOS polymorphism and idiopathic osteonecrosis of the head of the femur. *JBJS*, 89(11), 2460-2468.
- Koo KH, Lee JS, Lee YJ, et al (2006). Endothelial nitric oxide synthase gene polymorphisms in patients with nontraumatic femoral head osteonecrosis. *Journal of orthopaedic research*, 24(8), 1722-1728.
- Riegersperger M, Covic A, Goldsmith D. (2011). Allopurinol, uric acid, and oxidative stress in cardiorenal disease. *International urology and nephrology*, 43(2), 441-449.
- Narayanan A, Khanchandani P, Borkar RM, et al (2017). Avascular necrosis of femoral head: a metabolomic, biochemical, electron microscopic and histopathological characterization. *Scientific reports*, 7(1), 1-16.
- Jones JJ (1992). Intravascular coagulation and osteonecrosis. *Clinical orthopaedics and related research*, (277), 41-53.
- Yoon BH, Kim TY, Shin IS, et al. (2017). Alcohol intake and the risk of osteonecrosis of the femoral head in Japanese populations: a dose-response meta-analysis of case-control studies. *Clinical rheumatology*, 36(11), 2517-2524.
- Gold EW, Cangemi PJ (1979). Incidence and pathogenesis of alcohol-induced osteonecrosis of the femoral head. *Clinical orthopaedics and related research*, (143), 222-226.
- Wang A, Ren M, Wang J. (2018). The pathogenesis of steroid-induced osteonecrosis of the femoral head: a systematic review of the literature. *Gene*, 671, 103-109.
- Sakaguchi M, Tanaka T, Fukushima W, et al (2010). Impact of oral corticosteroid use for idiopathic osteonecrosis of the femoral head: a nationwide multicenter case-control study in Japan. *Journal of Orthopaedic Science*, 15(2), 185-191.
- Hirota Y, Hirohata T, Fukuda K, et al (1993). Association of alcohol intake, cigarette smoking, and occupational status with the risk of idiopathic osteonecrosis of the femoral head. *American journal of epidemiology*, 137(5), 530-538.
- Liu YF, Chen WM, Lin YF, et al (2005). Type II collagen gene variants and inherited osteonecrosis of the femoral head. *New England Journal of Medicine*, 352(22), 2294-2301.
- Powell C, Chang C, Naguwa SM, et al (2010). Steroid induced osteonecrosis: an analysis of steroid dosing risk. *Autoimmunity reviews*, 9(11), 721-743.
- Addae S, Adzaku F, Mohammed S, et al (1990). Sickle cell disease in permanent residents of mountain and low altitudes in Saudi Arabia. *Tropical and geographical medicine*, 42(4), 342-348.
- Mitchell MJ, Logan PM. (1998). Radiation-induced changes in bone. *Radiographics*, 18(5), 1125-1136..
- Coulthard A, Pooley J, Reed J, et al. (1996). Pathophysiology of dysbaric osteonecrosis: a magnetic resonance imaging study.
- Krenn V, Müller S, Krenn VT, et al. (2018). Pathophysiology of aseptic femoral head necrosis: Pathogenesis and histopathological differential diagnosis. *Der Orthopäde*, 47(9), 710-716.
- Moon ES, Mehlman CT. (2006). Risk factors for avascular necrosis after femoral neck fractures in children: 25 Cincinnati cases and meta-analysis of 360 cases. *Journal of orthopaedic trauma*, 20(5), 323-329.
- Yoo WJ, Choi IH, Chung CY, et al. (2004). Valgus femoral osteotomy for hinge abduction in Perthes' disease: decision-making and outcomes. *The Journal of bone and joint surgery. British volume*, 86(5), 726-730.
- Kim HY, Cha YH, Choy WS, et al. (2018). Femoral head wedge resection for the treatment of avascular necrosis of the femoral head after pediatric femoral neck fracture: a case report. *Journal of pediatric orthopedics. Part B*, 27(3), 283.

32. Darabi K, Arshi S, Nabavi M, et al. (2018). Steroid Induce of Avascular Necrosis of Femoral Head in Chronic Urticarial. *Iranian Journal of Allergy, Asthma & Immunology*, 17.
33. Kameda H, Amano K, Nagasawa H, et al. (2009). Notable difference between the development of vertebral fracture and osteonecrosis of the femoral head in patients treated with high-dose glucocorticoids for systemic rheumatic diseases. *Internal Medicine*, 48(22), 1931-1938.
34. Shigemura T, Nakamura J, Kishida S, et al. (2011). Incidence of osteonecrosis associated with corticosteroid therapy among different underlying diseases: prospective MRI study. *Rheumatology*, 50(11), 2023-2028.
35. Mont MA, Pivec R, Banerjee S, et al. (2015). High-dose corticosteroid use and risk of hip osteonecrosis: meta-analysis and systematic literature review. *The Journal of arthroplasty*, 30(9), 1506-1512.
36. Flouzat-Lachaniette CH, Roubineau F, Heyberger C, et al. (2016). Multifocal osteonecrosis related to corticosteroid: ten years later, risk of progression and observation of subsequent new osteonecroses. *International orthopaedics*, 40(4), 669-672.
37. Egger AC, Ballock RT. (2017). Osteonecrosis of the femoral head in an adolescent on long-term inhalational corticosteroids. *Case reports in pediatrics*, 2017.
38. Wood TJ, Hoppe DJ, Winemaker M, et al (2016). Bilateral osteonecrosis of the femoral head during pregnancy following two corticosteroid injections: A case report and review of the literature. *Cureus*, 8(4).
39. Yang Y, Fan H, Huang J, et al. (2016). Establishment of a rat model of alcohol-induced avascular necrosis of the femoral head. *Chinese Journal of Tissue Engineering Research*, 20(27), 3977-3983.
40. Hasse B, Ledergerber B, Egger M, et al (2004). Antiretroviral treatment and osteonecrosis in patients of the Swiss HIV Cohort Study: a nested case-control study. *AIDS Research & Human Retroviruses*, 20(9), 909-915.
41. Glueck CJ, Freiberg RA, Wang P. (2008). Heritable thrombophilia-hypofibrinolysis and osteonecrosis of the femoral head. *Clinical orthopaedics and related research*, 466(5), 1034-1040.
42. Adikari M, Gunawardane A, Illangantilaka S, et al. (2016). A case of systemic lupus erythematosus presenting as bilateral avascular necrosis of femur. *BMC research notes*, 9(1), 392.
43. Kuroda T, Tanabe N, Wakamatsu A, et al (2015). High triglyceride is a risk factor for silent osteonecrosis of the femoral head in systemic lupus erythematosus. *Clinical rheumatology*, 34(12), 2071-2077.
44. Ficat RP. (1985). Idiopathic bone necrosis of the femoral head. Early diagnosis and treatment. *The Journal of bone and joint surgery. British volume*, 67(1), 3-9.
45. Steinberg ME, Hayken GD, Steinberg DR. (1995). A quantitative system for staging avascular necrosis. *The Journal of bone and joint surgery. British volume*, 77(1), 34-41.
46. Sugano N, Atsumi T, Ohzono K, et al. (2002). The 2001 revised criteria for diagnosis, classification, and staging of idiopathic osteonecrosis of the femoral head. *Journal of orthopaedic science*, 7(5), 601-605.
47. Kerboul M, Thomine J, Postel M, et al. (1974). The conservative surgical treatment of idiopathic aseptic necrosis of the femoral head. *The Journal of bone and joint surgery. British volume*, 56(2), 291-296.
48. Schmitt-Sody M, Kirchhoff C, Mayer W, et al. (2008). Avascular necrosis of the femoral head: inter- and intraobserver variations of Ficat and ARCO classifications. *International orthopaedics*, 32(3), 283-287.
49. Mont MA, Marulanda GA, Jones LC, et al. (2006). Systematic analysis of classification systems for osteonecrosis of the femoral head. *JBJS*, 88(suppl_3), 16-26.
50. Steinberg ME, Steinberg DR. (2004). Classification systems for osteonecrosis: an overview. *Orthopedic Clinics*, 35(3), 273-283.
51. Plakseychuk AY, Shah M, Varitimidis SE, et al. (2001). Classification of Osteonecrosis of the Femoral Head: Reliability, Reproducibility, and Prognostic Value. *Clinical Orthopaedics and Related Research (1976-2007)*, 386, 34-41.
52. Karatoprak O, Korkmaz M, Kara A, et al. (2008). Early results of autologous mononuclear bone marrow cell transplantation in nontraumatic avascular necrosis of the femoral head. *Acta orthopaedica et traumatologica turcica*, 178-183.
53. Hernigou P, Poignard A, Nogier A, et al. (2004). Fate of very small asymptomatic stage-I osteonecrotic lesions of the hip. *JBJS*, 86(12), 2589-2593.
54. Takatori Y, Kokubo T, Ninomiya S, et al. (1993). Avascular necrosis of the femoral head. Natural history and magnetic resonance imaging. *The Journal of bone and joint surgery. British volume*, 75(2), 217-221.
55. Takashima K, Sakai T, Hamada H, et al. (2018). Which classification system is most useful for classifying osteonecrosis of the femoral head?. *Clinical orthopaedics and related research*, 476(6), 1240.
56. Ohzono K, Saito M, Takaoka K, et al. (1991). Natural history of nontraumatic avascular necrosis of the femoral head. *The Journal of bone and joint surgery. British volume*, 73(1), 68-72.
57. Arbab D, König DP. (2016). Atraumatic femoral head necrosis in adults: epidemiology, etiology, diagnosis and treatment. *Deutsches Ärzteblatt International*, 113(3), 31.
58. Roth A, Beckmann J, Bohndorf K, et al. (2016). S3-Guideline non-traumatic adult femoral head necrosis. *Archives of orthopaedic and trauma surgery*, 136(2), 165-174.
59. Ando W, Yamamoto K, Koyama T, et al. (2017). Radiologic and Clinical Features of Misdiagnosed Idiopathic Osteonecrosis of the Femoral Head. *Orthopedics*, 40(1), e117-e123.
60. Aiello MR, Chew FS. (2012). Imaging in avascular necrosis of the femoral head.
61. Pivec R, Johnson AJ, Mont MA. (2013). Differentiation, diagnosis, and treatment of osteoarthritis, osteonecrosis, and rapidly progressive osteoarthritis. *Orthopedics*, 36(2), 118-125.
62. Mitchell DG, Kressel HY, Arger PH, et al. (1986). Avascular necrosis of the femoral head: morphologic assessment by MR imaging, with CT correlation. *Radiology*, 161(3), 739-742.

63. Yeh LR, Chen CK, Huang YL, et al. (2009). Diagnostic performance of MR imaging in the assessment of subchondral fractures in avascular necrosis of the femoral head. *Skeletal radiology*, 38(6), 559-564.
64. Stevens K, Tao C, Lee SU, et al (2003). Subchondral fractures in osteonecrosis of the femoral head: comparison of radiography, CT, and MR imaging. *American Journal of Roentgenology*, 180(2), 363-368.
65. Barile MF, Wu JS, McMahon CJ. (2014). Femoral head avascular necrosis: a frequently missed incidental finding on multidetector CT. *Clinical radiology*, 69(3), 280-285.
66. Zhao DW, Hu YC. (2012). Chinese experts' consensus on the diagnosis and treatment of osteonecrosis of the femoral head in adults. *Orthopaedic surgery*, 4(3), 125-130.
67. Lang P, Genant HK, Jergesen HE, et al (1992). Imaging of the hip joint. Computed tomography versus magnetic resonance imaging. *Clinical orthopaedics and related research*, (274), 135-153.
68. Huang GS, Chan WP, Chang YC, et al (2003). MR imaging of bone marrow edema and joint effusion in patients with osteonecrosis of the femoral head: relationship to pain. *American Journal of Roentgenology*, 181(2), 545-549.
69. Zhao FC, Li ZR, Zhang NF, et al. (2010). Lesion size changes in osteonecrosis of the femoral head: a long-term prospective study using MRI. *International orthopaedics*, 34(6), 799-804.
70. Buchan CA, Pearce DH, Lau J, et al (2012, July). Imaging of postoperative avascular necrosis of the ankle and foot. In *Seminars in musculoskeletal radiology* (Vol. 16, No. 03, pp. 192-204). Thieme Medical Publishers.
71. Mueller D, Schaeffeler C, Baum T, et al. (2014). Magnetic resonance perfusion and diffusion imaging characteristics of transient bone marrow edema, avascular necrosis and subchondral insufficiency fractures of the proximal femur. *European journal of radiology*, 83(10), 1862-1869.
72. Mont MA, Ulrich SD, Seyler TM, et al. (2008). Bone scanning of limited value for diagnosis of symptomatic oligofocal and multifocal osteonecrosis. *The Journal of rheumatology*, 35(8), 1629-1634.
73. Fontecha CG, Roca I, Barber I, et al. (2016). Femoral head bone viability after free vascularized fibular grafting for osteonecrosis: SPECT/CT study. *Microsurgery*, 36(7), 573-577.
74. Dasa V, Adbel-Nabi H, Anders MJ, et al. (2008). F-18 fluoride positron emission tomography of the hip for osteonecrosis. *Clinical orthopaedics and related research*, 466(5), 1081-1086.
75. Berg BCV, Lecouvet FE, Koutaissoff S, et al. (2008). Bone marrow edema of the femoral head and transient osteoporosis of the hip. *European journal of radiology*, 67(1), 68-77.
76. Vande Berg BC, Malghem JJ, Lecouvet FE, et al. (1999). Idiopathic bone marrow edema lesions of the femoral head: predictive value of MR imaging findings. *Radiology*, 212(2), 527-535.
77. Vande Berg BC, Malghem J, Goffin EJ, et al. (1994). Transient epiphyseal lesions in renal transplant recipients: presumed insufficiency stress fractures. *Radiology*, 191(2), 403-407.
78. Wilson AJ, Murphy WA, Hardy DC, et al (1988). Transient osteoporosis: transient bone marrow edema?. *Radiology*, 167(3), 757-760.
79. Ikemura S, Yamamoto T, Motomura G, et al. (2010). MRI evaluation of collapsed femoral heads in patients 60 years old or older: differentiation of subchondral insufficiency fracture from osteonecrosis of the femoral head. *American Journal of Roentgenology*, 195(1), W63-W68.
80. Balakrishnan A, Schemitsch EH, Pearce D, et al. (2003). Distinguishing transient osteoporosis of the hip from avascular necrosis. *Canadian journal of surgery*, 46(3), 187.
81. Hofmann S, Kramer J, Schneider W, et al. (1997). (ii) Transient osteoporosis may represent a reversible early form of avascular necrosis of the hip joint. *Current Orthopaedics*, 11(3), 164-172.
82. Yamamoto T, Schneider R, Bullough PG. (2001). Subchondral insufficiency fracture of the femoral head: histopathologic correlation with MRI. *Skeletal radiology*, 30(5), 247-254.
83. Ikemura S, Yamamoto T, Motomura G, et al. (2010). MRI evaluation of collapsed femoral heads in patients 60 years old or older: differentiation of subchondral insufficiency fracture from osteonecrosis of the femoral head. *American Journal of Roentgenology*, 195(1), W63-W68.
84. Malizos KN, Zibis AH, Dailiana Z, et al. (2004). MR imaging findings in transient osteoporosis of the hip. *European journal of radiology*, 50(3), 238-244.
85. Menezes NM, Connolly SA, Shapiro F, et al. (2007). Early ischemia in growing piglet skeleton: MR diffusion and perfusion imaging. *Radiology*, 242(1), 129-136.
86. Steinberg ME, Oh SC, Khoury V, et al. (2018). Lesion size measurement in femoral head necrosis. *International orthopaedics*, 42(7), 1585-1591.
87. Kang P, Pei F, Shen B, et al. (2012). Are the results of multiple drilling and alendronate for osteonecrosis of the femoral head better than those of multiple drilling? A pilot study. *Joint Bone Spine*, 79(1), 67-72.
88. Aigner N, Petje G, Schneider W, et al. (2005). Bone marrow edema syndrome of the femoral head. *Wiener klinische Wochenschrift*, 117(4), 130-135.
89. Ajmal M, Matas AJ, Kuskowski M, et al. (2009). Does statin usage reduce the risk of corticosteroid-related osteonecrosis in renal transplant population? *Orthopedic Clinics of North America*, 40(2), 235-239.
90. Reis ND, Schwartz O, Militianu D, et al. (2003). Hyperbaric oxygen therapy as a treatment for stage-I avascular necrosis of the femoral head. *The Journal of bone and joint surgery*. British volume, 85(3), 371-375.
91. Ludwig J, Lauber S, Lauber HJ, et al. (2001). High-energy shock wave treatment of femoral head necrosis in adults. *Clinical Orthopaedics and Related Research*, 387, 119-126.
92. He Q, Tian L, Jiang H, et al. (2017). Identification of laryngeal cancer prognostic biomarkers using an inflammatory gene-related, competitive endogenous RNA network. *Oncotarget*, 8(6), 9525.

93. Janssens GO, Rademakers SE, Terhaard CH, et al. (2012). Accelerated radiotherapy with carbogen and nicotinamide for laryngeal cancer: results of a phase III randomized trial. *Journal of clinical oncology*, 30(15), 1777-1783.
94. Geng J, Liu Y, Jin Y, et al. (2016). MicroRNA-365a-3p promotes tumor growth and metastasis in laryngeal squamous cell carcinoma. *Oncology reports*, 35(4), 2017-2026.
95. Huang D, Li Z, Chen B, et al. (2018). Naringin protects against steroid-induced avascular necrosis of the femoral head through upregulation of PPAR γ and activation of the Notch signaling pathway. *Molecular medicine reports*, 17(2), 3328-3335.
96. Yan YQ, Pang QJ, Xu RJ. (2018). Effects of erythropoietin for precaution of steroid-induced femoral head necrosis in rats. *BMC musculoskeletal disorders*, 19(1), 1-7.
97. Houdek MT, Wyles CC, Packard BD, et al. (2016). Decreased osteogenic activity of mesenchymal stem cells in patients with corticosteroid-induced osteonecrosis of the femoral head. *The Journal of arthroplasty*, 31(4), 893-898.
98. Lieberman JR, Engstrom SM, Meneghini RM, et al. (2012). Which factors influence preservation of the osteonecrotic femoral head? *Clinical Orthopaedics and Related Research* «, 470(2), 525-534.
99. Hasegawa Y, Sakano S, Iwase T, et al. (2003). Pedicle bone grafting versus transtrochanteric rotational osteotomy for avascular necrosis of the femoral head. *The Journal of bone and joint surgery. British volume*, 85(2), 191-198.
100. Pakos EE, Megas P, Paschos NK, et al (2015). Modified porous tantalum rod technique for the treatment of femoral head osteonecrosis. *World journal of orthopedics*, 6(10), 829.
101. Kim YH, Oh SH, Kim JS, et al (2003). Contemporary total hip arthroplasty with and without cement in patients with osteonecrosis of the femoral head. *JBJS*, 85(4), 675-681.
102. Johansson HR, Zywił MG, Marker DR, et al. (2011). Osteonecrosis is not a predictor of poor outcomes in primary total hip arthroplasty: a systematic literature review. *International orthopaedics*, 35(4), 465-473.
103. Radl R, Hungerford M, Materna W, et al. (2005). Higher failure rate and stem migration of an uncemented femoral component in patients with femoral head osteonecrosis than in patients with osteoarthritis. *Acta orthopaedica*, 76(1), 49-55.